

Use of a Transcutaneous Carboxytherapy Gel for Treating Small Diabetic Foot Ulcers: Preliminary Investigations

Lynda Khiat¹ and Gustavo H Leibaschoff^{2*}

¹Faculté de Médecine D'Oran Oran, Algeria

²International Consultants in Aesthetic Medicine (ICAM USA LLC) Dallas, TX, USA

*Corresponding author

Gustavo H Leibaschoff, International Consultants in Aesthetic Medicine, 9100 S Dadeland Boulevard, Suite 912, Miami, FL 33156, USA.

Received: October 26, 2024; **Accepted:** November 04, 2024; **Published:** November 08, 2024

ABSTRACT

Diabetes mellitus (DM) is a chronic metabolic disease affecting millions of people worldwide. One of the many complications of poorly controlled diabetes is chronic nonhealing diabetic foot ulcers which are a significant cause of hospitalization and increase the risk of amputation. Previously, we demonstrated the beneficial effects of transdermal carboxytherapy for treating patients with diabetic ulcers; however, topical carboxytherapy has emerged as a viable noninvasive adjunct for wound healing. Here, we present our initial observations following the addition of a topical CO₂ gel to standard wound care for treating small diabetic foot ulcers (CO₂ LIFT® Carboxy Gel, Lumisque, Inc.; Weston, FL USA). The product was provided as two components which, when combined, generate CO₂ gas for 45 minutes. The CO₂ gel was applied at home to foot ulcers three times weekly for 1 month with a sterile spatula. The gel was left in place for 45 minutes and then removed with the spatula. Patients also received oral antibiotics. All ten subjects demonstrated significant clinical after 4 weeks; however, one patient experienced delayed healing due to atheromatous arterial disease, insufficiency in the great saphenous vein, and Boyd perforante. These results suggest real clinical benefits of a transcutaneous carboxytherapy gel as an adjunct for treating subjects with small diabetic foot ulcers. This non-invasive therapy is well-suited for routine home management. A larger, randomized, controlled study is needed to confirm these promising results.

Keywords: Diabetes Mellitus, Carboxytherapy, Diabetic Foot Ulcers, Wound Healing, Preliminary Observations

Introduction

Diabetes mellitus (DM) is a chronic metabolic disease characterized by hyperglycemia resulting from inadequate insulin secretion, faulty insulin action, or both [1-3]. DM is a major global health issue affecting as estimated 382 million people. The global prevalence of diabetes is growing, and by 2035 an estimated 592 million people will be affected [4]. The long-term effects of DM may include multiple organ and tissue damage leading to debilitating health complications including skin ulcerations [5-7].

Carboxytherapy

Carboxytherapy originally referred to the subcutaneous injection of CO₂ gas to improve microcirculation, increase tissue oxygen levels, and promote wound-healing. When injected subcutaneously, CO₂ immediately diffuses at the cutaneous and muscular microcirculatory levels, producing microcirculatory

vasodilatation, and improving blood flow through a direct action on arteriole smooth muscle cells via the Bohr effect [8]. In response to increased CO₂ and decreased pH, there is a right-ward shift of the oxygen-hemoglobin dissociation curve which enhances the release of O₂ from the blood into the surrounding tissues.

To assess the beneficial effects of transdermal carboxytherapy for treating diabetic ulcers, the authors initially performed a prospective clinical study with patients presenting with different types and sizes of chronic foot ulcers (N=40) [9]. The treatment protocol included wound cleaning, debridement as needed, antibiotics, blood sugar control, medication, healthy habits, no weight-bearing, and subcutaneous injections of CO₂. The results of that study demonstrated that this treatment protocol, including carboxytherapy, promoted wound healing and prevented amputation.

Work by other investigators at this time suggested the topical application of CO₂ in the form of a hydrogel was beneficial for

Citation: Lynda Khiat, Gustavo H Leibaschoff. Use of a Transcutaneous Carboxytherapy Gel for Treating Small Diabetic Foot Ulcers: Preliminary Investigations.. *J Clin Res Case Stud.* 2024. 2(4): 1-4. DOI: doi.org/10.61440/JCRCS.2024.v2.54

wound healing in animal models [10,11]. In addition, the results of a clinical study showed that soaking diabetic ulcers in water saturated with CO₂ improved circulation and enhanced wound healing [12]. Another clinical study showed the topical application of gaseous CO₂ also improved the healing of diabetic ulcers [13].

We became interested in exploring the use of topical CO₂ for diabetic ulcers following the recent availability of a novel, topical carboxytherapy gel (CO₂Lift® Carboxy Gel. Lumisque, Inc.; Weston, FL USA). The product is provided as two components which, when combined, generates CO₂ gas for 45 minutes. The gel is applied to the lesion, left in place for 45 minutes, and then removed with the applicator spatula. In contrast to other forms of topical carboxytherapy, this commercially available product is well-suited for home use.

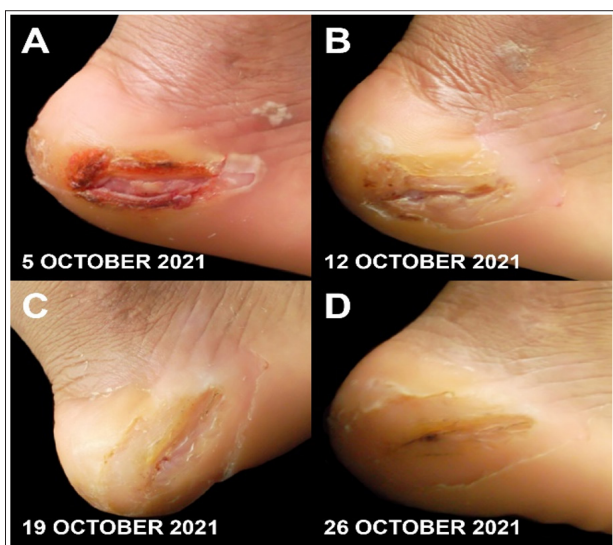

Figure 1: This patient had superficial ulceration limited by hyperkeratosis (1A). After 4 weeks, the patient achieved complete healing with residual hyperkeratosis with thick plantar skin (1D).

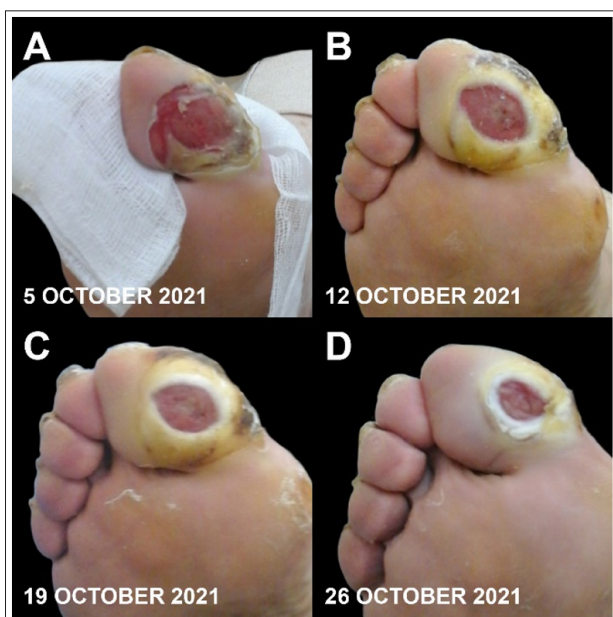

Figure 2: The lesions on this patient showed superficial ulceration and hyperkeratosis, an abnormal thickening of the outermost layer of the skin (2A). Assessment after 4 weeks showed a budding wound, suggesting effective wound healing. Indeed, a budding wound is the sign of optimal recovery of vascularization (2D).

Materials And Methods

The objective of this observational study was to add the transdermal CO₂ gel to our current standard of care for treating small diabetic foot ulcers. Each subject provided written informed consent and expressed their willingness to adhere to study requirements. As these patients were undergoing normal care for their diabetic lesions, no trial registration was deemed necessary for this preliminary observational report.

Laboratory studies included BUN and creatinine, hemoglobin A1C, osteomyelitis screening (CRP>10 and ESR>40), hematology assessment, deep wound bacteriology study and antibiogram, lower limb ecdoppler vascular multifrequency linear probe, and radiographs of the foot. Treatment included wound cleaning and debridement as needed, antibiotics, and blood sugar management. Patients were provided with a home supply of the CO₂ gel product (CO₂LIFT®) and detailed written instructions for its use. The CO₂ gel was applied to foot ulcers at home three times weekly for 4 weeks.

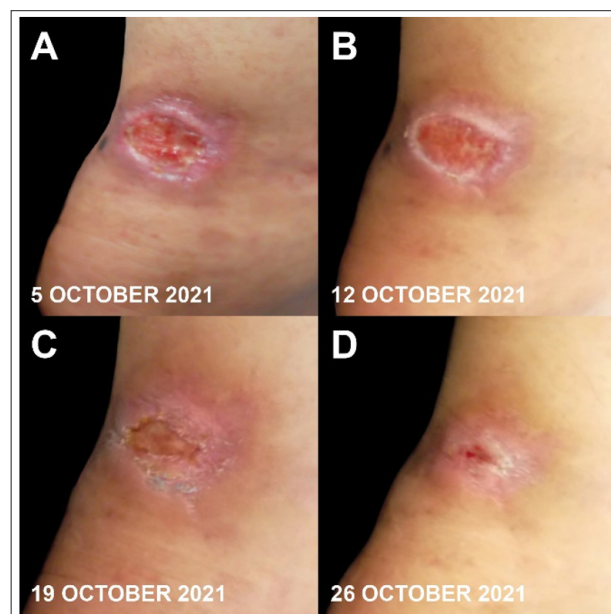

Figure 3: Panel 3A shows superficial ulceration next to the Achilles tendon with complete healing of the lesion (3D) after 4 weeks.

Results

The patients included in this report had small diabetic foot ulcers with no anaerobic bacterial infections or osteitis (N=10). Patient ages ranged from 13 to 67 years. Nine had type 2 DM and one had type 1 DM. Eight were receiving blood sugar control with insulin. Nonhealing ulcers were located on the external malleolus (n=2), inner supra malleolus, inner lateral foot (n=2), great toe (n=2), multiple toes (burn injury), heel, and Achilles tendon. For eight patients, wound cultures were positive for gram-positive bacteria including *Staphylococcus aureus*. Current antibiotic therapies were fusidic acid 500 mg twice-daily for 4 weeks (n=6) or 2 weeks (n=2), metronidazole 500 mg plus ciprofloxacin 500 mg daily for 5 weeks (n=1), and metronidazole 500 mg twice daily plus cefazoline 1 g daily for 5 weeks (n=1). After 4 weeks, most patients achieved complete or advanced wound healing. In one patient, a lower-limb doppler echo revealed diffuse atheromatous arterial disease, insufficiency in the great saphenous vein, and

Boyd perforante. In this patient, problems associated with varicose veins delayed healing. There were no treatment-related adverse events.

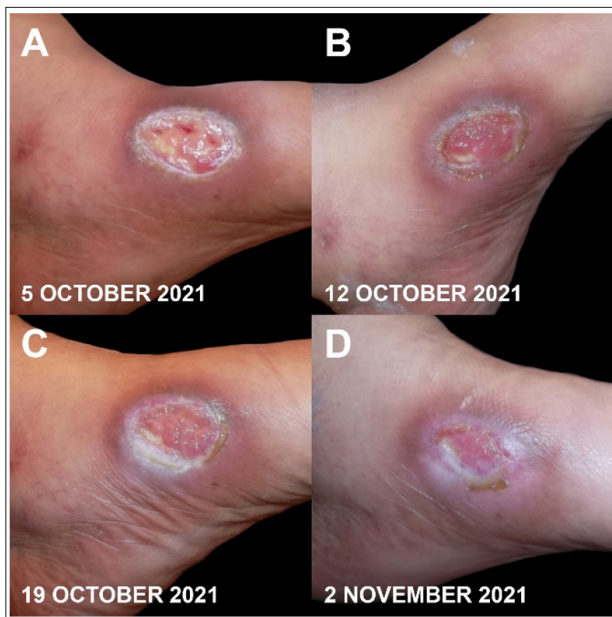


Figure 4: The patient presented with a weeping wound (4A). The wound was in the process of good healing after 4 weeks (4D).

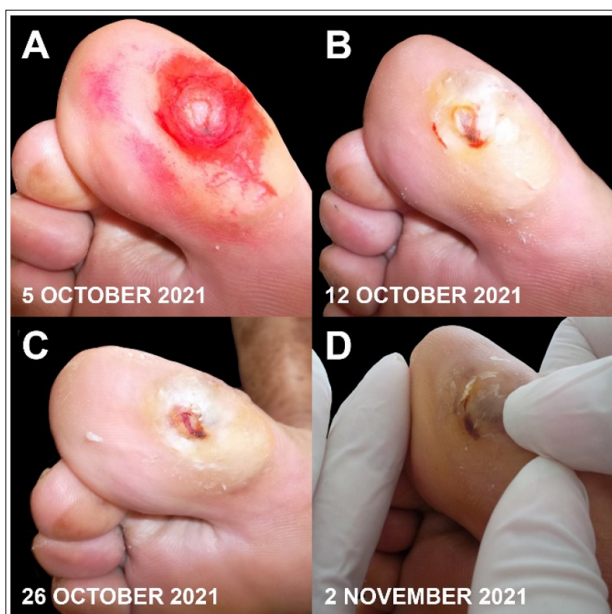

Figure 5: The initial superficial ulcer is shown in 5A. Complete healing with residual hyperkeratosis after 4 weeks is evident (5D).

Discussion

Carboxytherapy owes its therapeutic effects to increasing tissue oxygen availability and enhancing microcirculation. Increased oxygen and release of growth factors from blood within the treatment area stimulates fibroblasts to produce collagen and the formation of new blood vessels through neovascularization [14]. Prior to the present observational study, the authors investigated the effects of topical carboxytherapy gel (CO₂Lift®) on the peripheral vasculature [15]. In that study, volunteer subjects received three weekly applications of CO₂ gel on an earlobe for 1 month. There was a 43.2% increase in vertical capillaries in the treated tissue and capillaries showed a mean 26.8% increase in capillary density and a 27.7% increase in blood flow. These

results were similar to those observed in other studies with injected CO₂ gas [16].

Diabetic foot ulcers are a common complication in this patient population [17]. Treatment can be complex, requiring a multidisciplinary approach, and is not always successful. Recurrence of ulcers is not uncommon [18]. The objective of the preliminary study presented here was to further assess the safety and efficacy of transdermal CO₂ gel as an adjunct for treating small diabetic foot ulcers. Most of these patients demonstrated significant clinical improvement with the use of antibiotics and the application of a transdermal CO₂ gel applied to foot ulcers three times weekly for 4 weeks. These results compare favorably with other previous studies demonstrating a beneficial effect from topical CO₂ on diabetic ulcer healing [19]. Treatment was well-tolerated with no reported adverse events. Importantly, we believe the carboxytherapy product used in the present study is the only commercially available product suitable for home use. Further studies of carboxytherapy for the treatment of diabetic foot ulcers are warranted.

Conclusion

The results of this prospective short-term study demonstrated real clinical benefit of a transcutaneous carboxytherapy gel for treating subjects with small diabetic foot ulcers, thereby avoiding severe complications. This non-invasive carboxytherapy is well-suited for routine home management of small diabetic foot ulcers. A larger, randomized, control study is needed to confirm these promising results.

Financial Disclosures, Conflicts of Interest:

Dr. Lynda Khiat reports nothing to disclose.

Dr. Gustavo H. Leibaschoff reports nothing to disclose.

Running head: Carboxytherapy Gel for Diabetic Foot Ulcers

Acknowledgement

The authors acknowledge the editorial assistance of Dr. Carl S. Hornfeldt, Apothekon, Inc., during the preparation of this manuscript.

References

1. American Diabetes Association. Diagnosis and classification of diabetes mellitus. *Diabetes Care*. 2005. 28: 37-42.
2. Zou Q, Qu K, Luo Y, Yin D, Ju Y, et al. Predicting diabetes mellitus with machine learning techniques. *Front Genet*. 2018. 9: 515.
3. Mane K, Chaluvvaraju K, Niranjana M, Zaranappa T, Manjuthaj T. Review of insulin and its analogues in diabetes mellitus. *J Basic Clin Pharm*. 2012. 3: 283.
4. Kharroubi AT, Darwish HM. Diabetes mellitus: The epidemic of the century. *World J Diab*. 2015. 6: 850-867
5. Satirapoj B. Nephropathy in diabetes. *Diabetes*. Springer. 2013. 107-122.
6. Hartnett ME, Baehr W, Le YZ. Diabetic retinopathy, an overview. *Vision Res*. 2017;139:1-6.
7. Pearce I, Simó R, Lövestam-Adrian M, Wong DT, M E. Association between diabetic eye disease and other complications of diabetes: Implications for care. A systematic review. *Diabetes Obes Metab*. 2019. 21: 467-478.

8. Bohr C, Hasselbalch K, Krogh A. Concerning a biologically important relationship - the influence of the carbon dioxide content of blood on its oxygen binding. *Skand Arch Physiol*. 1904. 16: 401-412.
9. Khiat L, Leibaschoff GH. Clinical prospective study on the use of subcutaneous carboxytherapy in the treatment of diabetic foot ulcer. *Surg Technol Int*. 2018. 32: 81-90.
10. Nishimoto H, Inui A, Ueha T. Transcutaneous carbon dioxide application with hydrogel prevents muscle atrophy in a rat sciatic nerve crush model. *J Orthop Res*. 2018. 36: 1653-1658.
11. Kuroiwa Y, Fukui T, Takahara S. Topical cutaneous application of CO₂ accelerates bone healing in a rat femoral defect model. *BMC Musculoskelet Disord*. 2019. 20: 237.
12. Shalan N, Al-Bazzaz A, Al-Ani I, Najem F, Al-Masri M. Effect of carbon dioxide therapy on diabetic foot ulcer. *J Diabetes Mellitus*. 2015. 5: 284-289.
13. Macura M, Ban Frangez H, Cankar K, Finžgar M, Frangez I. The effect of transcutaneous application of gaseous CO₂ on diabetic chronic wound healing-A double-blind randomized clinical trial. *Int Wound J*. 2020. 17: 1607-1614.
14. Stolecka-Warzecha A, Chmielewski Ł, Deda A, Śmich A, Lebedowska A, et al. The influence of carboxytherapy on scar reduction. *Clin Cosmet Investig Dermatol*. 2022. 15: 2855-2872.
15. Leibaschoff GH, Coll L, Roberts WE. A prospective clinical and instrumental study on the effects of a transcutaneous cosmeceutical gel that is claimed to produce CO₂. *Surg Technol Int*. 2018. 32: 33-45.
16. Finžgar M, Melik Z, Cankar K. Effect of transcutaneous application of gaseous carbon dioxide on cutaneous microcirculation. *Clin Hemorheol Microcirc*. 2015. 60: 423-435.
17. Armstrong DG, Tan TW, Boulton AJM, Bus SA. Diabetic foot ulcers: A review. *JAMA*. 2023. 330: 62-75.
18. Sun Y, Zhou Y, Dai Y, Pan Y, Xiao Y, et al. Predictors of post-healing recurrence in patients with diabetic foot ulcers: A systematic review and meta-analysis. *J Tissue Viability*. 2024. 108-116.
19. Draelos ZD, Shamban A. A pilot study evaluating the anti-aging benefits of a CO₂-emitting facial mask. *J Cosmet Dermatol*. 2023. 22: 2198-2204.