

Subaortic Stenosis Due to Fibromuscular Shelf Diagnosed in a 64 years Woman with Dyspnea

Mineo V, Rebullia E, Camarda P, Valerio MCE, Castelluccio EV, Ardia GD, Candela P*

Cardiology department – Clinica Candela – Palermo, Italy

*Corresponding author

Candela P, Cardiology department – Clinica Candela – Palermo, Italy.

Received: June 12, 2024; Accepted: June 26, 2024; Published: July 01, 2024

Introduction

Subaortic stenosis is the second most common form of left ventricular outflow obstruction. It occurs when the flow of blood from the heart's pumping chamber or left ventricle is restricted. This obstruction is in the area of the heart under the aortic valve. There are three types of subaortic stenosis; two of them are associated with congenital heart disease (CHD). Subaortic membrane is the most common type. It is a shelf-like membrane that forms under the aortic valve. It causes obstruction to the flow of blood from the left ventricle into the aorta. This results in blood going through turbulence. A doctor hears this as a heart murmur. The subaortic membrane is twice as common in males. It has been reported in family clusters. It is more severe when diagnosed in children, rather than in adults. When detected in childhood it commonly worsens over time. About 50% of patients with a subaortic membrane also have leakage of the aortic valve.

Case Report

In April 2024, a 64 years old woman was hospitalized in our department for dyspnea and occasional episodes of palpitation. She had history of hypertension, dyslipidemia and type II diabetes.

On the 2th of April she went to the Emergency Department for intense palpitation, with evidence at the ECG of newly diagnosed atrial fibrillation with rapid ventricular response, which was effectively cardioverted with endovenous amiodarone. On the 4th of April she had a cardiology consult in our institution and, since the evidence of dyspnea and a 3/6 systolic ejection murmur at right sternal border, she was hospitalized.

The patient presented into NYHA class IV, without clinical signs of congestion.

- Body weight at admission 57 Kg
- NT pro BNP at admission 453 pg/ml

- Blood gas analysis: pH 7.56, pO₂ 112mmHg, pCO₂ 25mmHg Na⁺ 135 mmol/l, K⁺ 3.5 mmol/l, Cl⁻ 105mmol/l, Lac 1.9 mmol/l, Hb 12.1 g/dl; Be 0.2 mmol/l, HCO₃⁻ 22.4, satO₂ 100%.
- Renal function: presence of stage II chronic kidney disease, stable during the hospital stay (creatinine at discharge 0,58 mg/dl)
- ECG: sinus rhythm (57 bpm)
- Electrocardiographic monitoring: sinus bradycardia with heart rate trend of 55 bpm
- On the echocardiogram: left ventricle of normal size (LVEDV 55 ml/mq) with concentric hypertrophy (IVS 13 mm, LVMI 114 g/mq, RWT 0,54); no obvious segmental kinesis anomalies; normal systolic function (EF 60%); aorta of regular size where explorable; aortic valve morphology not evaluable (poor acoustic window) with regular opening but color Doppler features of severe aortic stenosis (Pvel 4 m/sec, MG 40 mmHg) and moderate aortic regurgitation; evidence of subaortic shelf; mild mitralic regurgitation; mildly enlarged left atrium (36 ml/mq); diastolic pattern with estimated normal filling pressures (average E/e' 13); mildly enlarged right atrium; right ventricle of normal size with reduced longitudinal systolic function indices (TAPSE 16 mm, S' at TDI 9 cm/sec); mild tricuspid regurgitation; normal size and collapse of IVC; undamaged pericardium (see figure 1).

We also performed transoesophageal echocardiogram during hospitalization: tricuspid aortic valve with normal opening; evidence of subaortic fibromuscular shelf causing severe obstruction to the flow of blood from the left ventricle to the aorta; moderate aortic regurgitation, due to the fibrosis of the aortic cusps, probably caused by the turbulence of the flow (see figure 2-5).

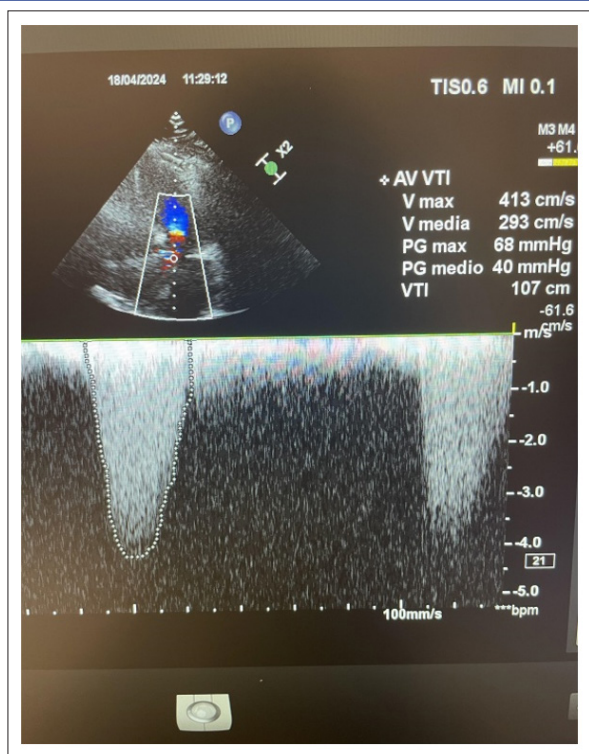


Figure 1

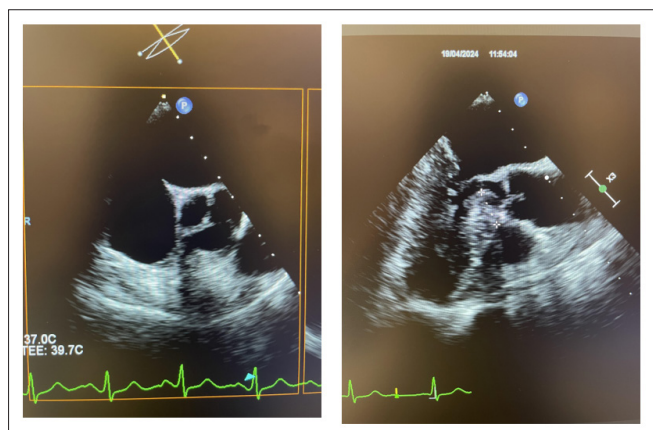


Figure 2

Figure 3

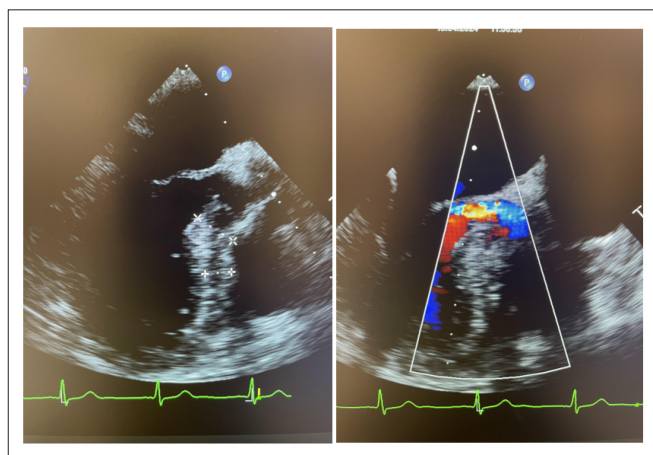


Figure 4

Figure 5

Discussion

The patient we present show a case of subvalvular aortic stenosis presenting with dyspnea and an episode of atrial fibrillation with rapid ventricular response. Transthoracic echocardiogram show a normal opening aortic valve, with color doppler data suggestive of severe aortic stenosis. Transoesophageal echocardiogram allowed to recognize the presence of a subaortic fibromuscular shelf, responsible for the sever obstruction to the blood flow into the aorta. In addition the turbulence of the flow caused fibrotic degeneration of the aortic cusps resulting into moderate aortic regurgitation. The patient will be evaluated by a cardiac surgeon in order to decide whether the fibromuscular shelf should be surgically removed.

References

1. Edwards JE. Pathology of Left Ventricular Outflow Tract Obstruction. *Circulation*. 1965. 31: 586-599.
2. Devabhaktuni SR, Chakfeh E, Malik AO, Pengson JA, Rana J, et al. Subvalvular aortic stenosis: a review of current literature. *Clin Cardiol*. 2018. 41: 131-136.
3. Amedeo Pergolini, Annachiara Pingitore, Giordano Zampi, Daniele Pontillo, Giovanni Menafra, et al. Critical subaortic stenosis due to fibromuscular ridge in a 66-year-old woman: 2D-3D echocardiography findings. *Ecocardiography*. 2010.