ISSN: 2977-0033

Case Report

Journal of Clinical Research and Case Studies

Sinonasal Lymphoma: A Case Report

Niema Benkhraba[1,3*], Wah sidelmoctar Abdallahi[1,3], Tarek dahan[1,3], Bencheikh Razika[2,3], Benbouzid Mohamed Anas[2,3] and Leila Essakalli Houssyni[2,3]

[1]*Resident physician in otorhinolaryngology, Department of Otorhinolaryngology, Head and Neck Surgery, Ibn Sina University Hospital, Rabat, Morocco*

[2]*Professor of otorhinolaryngology, Department of Otorhinolaryngology, Head and Neck Surgery, Ibn Sina University Hospital, Rabat, Morocco*

[3]*Faculty of Medicine and Pharmacy of Rabat, Mohammed V University, Rabat, Morocco*

[*]Corresponding author
Niema Benkhraba, Resident physician in otolaryngology, Department of Otolaryngology, Head and Neck Surgery, Ibn Sina University Hospital, Rabat, Morocco.

Received: August 12, 2024; **Accepted:** August 20, 2024; **Published:** August 24, 2024

ABSTRACT
Sinonasal lymphoma represent 1.5% of all lymphomas. Clinical presentations of sinonasal lymphoma vary according to the histological type of tumor. Histologic diagnosis with immunohistochemical confirmation is of utmost importance. Computed tomography/magnetic resonance imaging (CT/MRI) scans are done to stage the tumor locally and to check for the presence of metastasis. Treatment involved chemotherapy and Radiotherapy. We report the case of a 45-year-old patient, who consulted for a progressive left unilateral nasal obstruction, with mucopurulent rhinorrhea. Nasal endoscopy showed a polypoid formation obstructing the entire left nasal cavity. A biopsy was performed, revealing in favor of an infiltrating malignant tumor process of which lymphomatous origin is evoked requiring immunostaining for phenotyping. The immunohistochemical study concluded in lymphoma. This work was carried out to study the clinical presentation, location, histopathological diagnosis and immunohistochemical profile of sinonasal lymphomas.

Introduction

The nasal cavity and the paranasal sinuses are considered as a single functional unit affected by common pathological processes. Sinonasal tumors are tumors that occur in the nasal cavity or paranasal sinuses (PNS). These tumors are rare and account for only 3% of tumors in the upper respiratory tract [1,2]. They are twice as common in males than females and are usually seen in the fifth and sixth decades of life. Patients with sinonasal tumors present with vague complaints such as nasal obstruction, nasal congestion and discharge, headache and/or swelling and facial pain [3]. Diagnosis begins with a thorough clinical history and physical examination. Computed tomography/magnetic resonance imaging (CT/MRI) scans are done to stage the tumor locally and to check for the presence of metastasis [4].

Sinonasal lymphomas may manifest either in an isolated fashion or in conjunction with systemic disease. B-cell lymphomas, which account for most of these cases, carry a more favorable diagnosis, whereas extranodal natural killer cell lymphoma (ENKL) is associated with rapid disease progression and death [5]. Histologic diagnosis with immunohistochemical confirmation is of utmost importance, and clinicians should remain aware of this entity to differentiate it from other sinonasal malignancies [6].

Risk factors for Hodgkin's lymphoma include Ebstein–Barr Virus (EBV) infection and positive family history while risk factors for Non-Hodgkin's lymphoma (NHL) include autoimmune disease, HIV/AIDS, infection with human T lymphotropic virus, immunosuppressant medication and some pesticides [5]. The association of malignant lymphoma in the immune compromised or HIV patients has been discussed earlier, however, there are very few studies published describing the incidence of malignant sinonasal lymphoma in immunocompetent patients [7,8]. This work was carried out to study the clinical presentation, location, histopathological diagnosis and immunohistochemical profile of sinonasal lymphomas. We represent the case of a 45-year-old patient diagnosed with sinonasal lymphoma.

Case Report

This is a 45-year-old patient, who consulted for a progressive left unilateral nasal obstruction, with mucopurulent rhinorrhea. The clinical examination found a deformation of the face (left cheek tumefaction with inflammation of the skin). Nasal endoscopy

Citation: Niema Benkhraba, Kawtar Ayyad, Razika Bencheikh, Mohamed Anas Benbouzid, Abdelilah Oujilal, et al. Cystadenoma of the Tongue: A Case Report. J Clin Res Case Stud. 2024. 2(3): 1-3. DOI: doi.org/10.61440/JCRCS.2024.v2.46

showed a polypoid formation obstructing the entire left nasal cavity, covered with purulent secretions with a mass effect on the right nasal cavity. On the right side, there was an incomplete nasal obstruction related to the deviation of the septum in its anterior part (Figure 1). The remainder of the physical examination was normal, particularly the lymph node areas.

The CT scan finds a tissue lesional process at the level of the left nasal cavity enhanced after injection of PDC delimiting areas of necrosis, extended to the left ethmoidal cells, the homolateral maxillary sinus and the left nasal, genital and labial soft tissues with retentional sinusitis.

A biopsy was performed, revealing in favor of an infiltrating malignant tumor process of which lymphomatous origin is evoked requiring immunostaining for phenotyping. The immunohistochemical study concluded in lymphoma. Once the diagnosis of lymphoma was retained, an extension assessment was performed with a clinical neurological and ophthalmological examination, and in particular lymph node areas, which was normal. Biological examinations were normal, and the CT scan thoraco-abdominopelvic was normal. The patient received 5 courses of adjuvant chemotherapy according to the CHOP protocol (adriamycin + vincristine + cyclophosphamide +prednisone), followed by locoregional external radiation therapy (sinuses and nasal cavities). This radiochemotherapy was well tolerated by the patient. The evolution was favorable, without recurrence with a follow-up of 2 years.

Figure 1

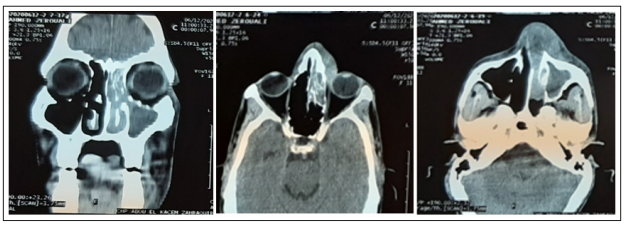

Figure 2: CT-scan (A: coronal sections, B and C: axial section): tumor process of the left nasal cavity extended to the left ethmoidal cells, to the homolateral maxillary sinus

Discussion

Malignant tumors of the sinonasal tract are extremely rare, accounting for 0.2% of all invasive cancers and 3% of the head-and-neck cancers. The majority arise in the maxillary sinus, approximately 20% arise in the ethmoid sinuses and the remainder (<1%) originate in the frontal and sphenoid sinuses. Squamous cell carcinoma is the most common histology, and lymphomas are uncommonly encountered [9]. The incidence of sinonasal lymphomas is higher in Asian countries than in the West; these malignancies account for 2.6%–6.7% of all lymphomas in Asia, and they are the second most common extranodal lymphoma, after gastrointestinal lymphoma [10]. Malignant lymphomas have a predilection for males, and they tend to occur in younger adults [11].

A large study by Peng et al. found that maxillary and ethmoid sinuses were affected more frequently (n = 8 patients each) than sphenoid and frontal sinuses (n = 5 patients each) [5]. However, another study by Logsdon et al. in Asian patients found nasal cavity as the main site of involvement [12]. According to Peng et al. the most common histological type of lymphoma is diffuse large B-cell lymphoma (53%), followed by ENKL/T-cell lymphoma, (21%).[5] On the contrary, according to Hatta et al. the most common histological type, in Japan, is angiocentric lymphoma (35.9%), followed by B-cell lymphoma (22.6%), peripheral T-cell lymphoma types (15.1%) and other lymphomas and non-specific types [13].

Clinical presentations of sinonasal lymphoma vary according to the histological type of tumor. Most of the low-grade lymphomas are associated with sinonasal mass along with obstructive symptoms and/or lymphadenopathy [14]. The high-grade lymphomas (38% of NHL in the sinonasal tract) are more likely to present with aggressive signs and symptoms including nonhealing ulcer, cranial nerve manifestations, facial swelling, epistaxis, pain, bony destruction or proptosis. T-cell lymphomas are associated with nasal septal perforation and/or destruction [15].

T-cell lymphomas are aggressive tumors, and histomorphologically, they are characterized by angiotropism or angiocentricity. The tumor cells infiltrate and destroy blood vessel walls and cause variable degrees of geographic necrosis. They express T-cell markers such as CD2, CD45RO and CD 43. They may also express CD 56, but the absence of CD 16 and CD 57 distinguishes them from typical NK cell lymphomas [16].

Extranasal dissemination occurs rarely in lymph nodes, skin and testes. At presentation, approximately 50% of patients have associated nodal disease, and only 20% report systemic or B symptoms [8]. There is a high incidence (15%) of extranodal relapse outside the gastrointestinal tract in patients with oral-sinonasal lymphoma to larynx, skin, liver, uvula, kidney, breast, lacrimal gland, testis and prostate gland [17].

Several types of mutation are known to occur in NHLs. In sinonasal lymphoma, the frequency of mutations in p53, K-ras, c-kit, beta-catenin and BAK gene is found with mutation frequency in all genes being higher in B-cell than in NKTCL cases [18]. These findings suggest that gene mutations might be the driving-force for B-cell lymphoma, whereas combined EBV infection and gene mutations contribute to NKTCL development [19,20].

Contrast-enhanced CT and MRI are done to assess the extent of the tumor, bone destruction, staging and also to decide the most suitable site of the biopsy. Treatment involved chemotherapy (CHOP regimen with cyclophosphamide, doxorubicin, vincristine and prednisolone) and Radiotherapy [12].

The prognosis depends on the type and stage of disease, the number of sites of extranodal spread, invasion of the central nervous system and the patient's general condition [20]. Patients with lymphomas of high histopathologic grade and recurrent or disseminated disease have the worst prognosis [21].

Correct diagnosis results from tissue biopsy, which should be performed in patients with any unilateral nasal mass. Early diagnosis and staging are essential for effective treatment, and lymphomas should always be included in the differential diagnosis of lesions of the nasal cavity and PNS.

Conclusion

Sinonasal lymphoma represent 1.5% of all lymphomas. It presents as an unremitting ulceration with progressive destruction of midline sinonasal and surrounding structures. Poor prognosis warrants early treatment although diagnosis is challenging and frequently delayed.

References

1. Isaacson PG, Chott A, Nakamura S, Muller-Hermelink HK, Harris NL, et al. Extranodal marginal zone lymphoma of mucosaassociated lymphoid tissue (MALT lymphoma). WHO classification of tumours of haematopoietic and lymphoid tissues. Lyon: IARC. 2008. 214-217.
2. Gaal K, Sun NC, Hernandez AM, Arber DA. Sinonasal NK/T-cell lymphomas in the United States. Am J Surg Pathol. 2000. 24: 1511-1517.
3. Hopkin N, McNicoll W, Dalley VM, Shaw HJ. Cancer of the paranasal sinuses and nasal cavities. Part I. Clinical features. J Laryngol Otol. 1984. 98: 585-595.
4. Kreisel FH. Hematolymphoid lesions of the sinonasal tract. Head Neck Pathol. 2016. 10: 109-117.
5. Peng KA, Kita AE, Suh JD, Bhuta SM, Wang MB. Sinonasal lymphoma: Case series and review of the literature. Int Forum Allergy Rhinol. 2014. 4: 670-674.
6. Ashraf MJ, Beigomi L, Azarpira N, Geramizadeh B, Khademi B, et al. The small round blue cell tumors of the sinonasal area: Histological and immunohistochemical findings. Iran Red Crescent Med J. 2013. 15: 455-461.
7. Steele TO, Buniel MC, Mace JC, El Rassi E, Smith TL. Lymphoma of the nasal cavity and paranasal sinuses: A case series. Am J Rhinol Allergy. 2016. 30: 335-339.
8. Vähämurto P, Silventoinen K, Vento SI, Karjalainen-Lindsberg ML, Haapaniemi A, et al. Clinical findings of extranodal SNT lymphoid malignancies in a four-decade single-centre series. Eur Arch Otorhinolaryngol. 2016. 273: 3839-3845.
9. Goldenberg D, Golz A, Fradis M, Mârtu D, Netzer A, et al. Malignant tumors of the nose and paranasal sinuses: A retrospective review of 291 cases. Ear Nose Throat J. 2001. 80: 272-277.
10. Aozasa K, Tsujimoto M, Sakurai M, Honda M, Yamashita K, et al. Non-Hodgkin's lymphomas in Osaka, Japan. Eur J Cancer Clin Oncol. 1985. 21: 487-492.
11. Danesh-Sani SA, Sarafraz A, Chamani M, Derakhshandeh H. Paranasal sinuses malignancies: A 12-year review of clinical characteristics. Med Oral Patol Oral Cir Bucal. 2016. 21: 626-630.
12. Logsdon MD, Ha CS, Kavadi VS, Cabanillas F, Hess MA, et al. Lymphoma of the nasal cavity and paranasal sinuses: Improved outcome and altered prognostic factors with combined modality therapy. Cancer. 1997. 80: 477-488.
13. Hatta C, Ogasawara H, Okita J, Kubota A, Ishida M, et al. Non-Hodgkin's malignant lymphoma of the sinonasal tract. Treatment outcome for 53 patients according to REAL classification. Auris Nasus Larynx. 2001. 28: 55-60.
14. Fasunla AJ, Lasisi AO. Sinonasal malignancies: A 10-year review in a tertiary health institution. J Natl Med Assoc. 2007. 99: 1407-1410.
15. Chalastras T, Elefteriadou A, Giotakis J, Soulandikas K, Korres S, et al. Non-Hodgkin's lymphoma of nasal cavity and paranasal sinuses. A clinicopathological and immunohistochemical study. Acta Otorhinolaryngol Ital. 2007. 27: 6-9.
16. Cleary KR, Batsakis JG. Sinonasal lymphomas. Ann Otol Rhinol Laryngol. 1994. 103: 911-914.
17. Abbondanzo SL, Wenig BM. Non-Hodgkin's lymphoma of the sinonasal tract. A clinicopathologic and immunophenotypic study of 120 cases. Cancer. 1995. 75: 1281-1291.
18. Kurniawan AN, Hongyo T, Hardjolukito ES, Ham MF, Takakuwa T, et al. Gene mutation analysis of sinonasal lymphomas in Indonesia. Oncol Rep. 2006. 15: 1257-1263.
19. Zhu K, Levine RS, Brann EA, Hall HI, Caplan LS, et al. Case-control study evaluating the homogeneity and heterogeneity of risk factors between sinonasal and nasopharyngeal cancers. Int J Cancer. 2002. 99: 119-123.
20. Hanna E, Wanamaker J, Adelstein D, Tubbs R, Lavertu P. Extranodal lymphomas of the head and neck. A 20-year experience. Arch Otolaryngol Head Neck Surg. 1997. 123: 1318-1323.
21. Campo E, Cardesa A, Alos L, Palacin A, Cobarro J, et al. Non-Hodgkin's lymphomas of nasal cavity and paranasal sinuses. An immunohistochemical study. Am J Clin Pathol. 1991. 96: 184-190.

Copyright: © 2024 Niema Benkhraba, et al. This is an open-access article distributed under the terms of the Creative Commons Attribution License, which permits unrestricted use, distribution, and reproduction in any medium, provided the original author and source are credited.