ISSN: 2977-0033

Research Article

Journal of Clinical Research and Case Studies

Labia Minora Reconstruction using a Labia Majora Flap for Female Genital Mutilation/Cutting and Botched Labiaplasty

Reham Awwad[1], Red Alinsod[2], Natalie Sorial[1,3] and Amr Seifeldin[1*]

[1]*Restore Clinic: Hosny Hospital, 25 Gameat Al Dewal Al Arabeya, Agouza, Giza Governorate, 3752241, Egypt*

[2]*Alinsod Institute of Aesthetic Vaginal Surgery, 8201 Preston Road Suite 520 Dallas TX 75225, USA*

[3]*University of Massachusetts Chan Medical School, 55 N Lake Ave, Worcester, MA 01653, USA*

[*]Corresponding author

Amr Seifledin, Urogynecologist and Aesthetic Gynecologist, Restore Clinic: 25 Gameat Al Dewal Al Arabeya, Agouza, Giza Governorate 3752241, Egypt.

Received: September 14, 2024; **Accepted:** September 23, 2024; **Published:** September 28, 2024

ABSTRACT

Existing techniques for labia minora reconstruction, developed for individuals with botched labiaplasties, currently rely on the surgical use of the clitoral hood, which is often absent in those who have undergone female genital cutting. This study introduces two novel approaches for labia minora reconstruction. Patients underwent bilateral or unilateral reconstruction as needed, and ultimately, all expressed satisfaction with no significant clinical complications observed. While longitudinal impact studies are warranted, this study introduces a surgical option for individuals with female genital cutting and botched labiaplasty seeking to restore the appearance of the excised labia minora. This pioneering reconstruction technique aspires to offer healing and empowerment, contributing to an overall more compassionate and comprehensive healthcare landscape for female genital mutilation/cutting survivors and botched labiaplasty patients.

Keywords: Female Genital Mutilation, Female Genital Cutting, Female Genital Mutilation/Cutting, Labia Minora Reconstruction, Botched Labiaplasty

Introduction

Female Genital Mutilation/Cutting

Female genital mutilation/cutting (FGM/C) is a widespread global practice observed in at least 92 countries [1]. Although the United Nations Sustainable Development Goal 5 aims to eliminate the practice by 2030, the stark reality remains that more than 230 million women currently alive have already undergone circumcision [2,3]. In Egypt alone, more than a staggering 31 million currently living women have experienced FGM/C, reflecting an alarming prevalence rate of 87% [4].

FGM/C is defined as the partial or total removal of female external genitalia for nonmedical reasons. The World Health Organization (WHO) classifies the degree of cutting into four categories, Types I-IV, considering the involvement of the glans clitoris, clitoral hood, labia minora, and labia majora. [5]. The removal of labia minora is categorized as Type II FGM/C and is one of the most common forms of FGM/C globally [6]. While rare, acute complications such as hematoma, sepsis, or urinary retention can pose life-threatening risks. Nevertheless, the majority of complications associated with FGM/C are chronic

For individuals experiencing functional complications, two surgical interventions are currently employed for treatment. For those facing complications resulting from infibulation, where a skin barrier is formed to cover the vaginal opening, such as chronic UTIs, menstrual problems, challenges in penetrative intercourse, or labor obstruction, defibulation is considered standard medical practice [7].

Defibulation (Figure 1) is a surgical procedure that involves a vertical incision through the seal of scar tissue narrowing the vaginal introitus, revealing the vulvar vestibule, vaginal orifice, external urethral meatus, and ultimately, the area of the glans clitoris. In the Seifeldin method, the wound is closed in two layers using a subcutaneous running stitch followed by superficial interrupted to best approximate the skin and resultant scar for the patient [8]. Candidacy for labia minora reconstruction after

Citation: Reham Awwad, Red Alinsod, Natalie Sorial, Amr Seifeldin. Labia Minora Reconstruction using a Labia Majora Flap for Female Genital Mutilation/Cutting and Botched Labiaplasty. J Clin Res Case Stud. 2024. 2(3): 1-11. DOI: doi.org/10.61440/JCRCS.2024.v2.53

defibulation is typically delayed for three to six months to allow for healing of the vulva. However, clitoral hood reconstruction, using a "W" incision with converging arms, may be done at the time of defibulation if enough skin is found.

Figure 1: defibulation, Seifeldin method

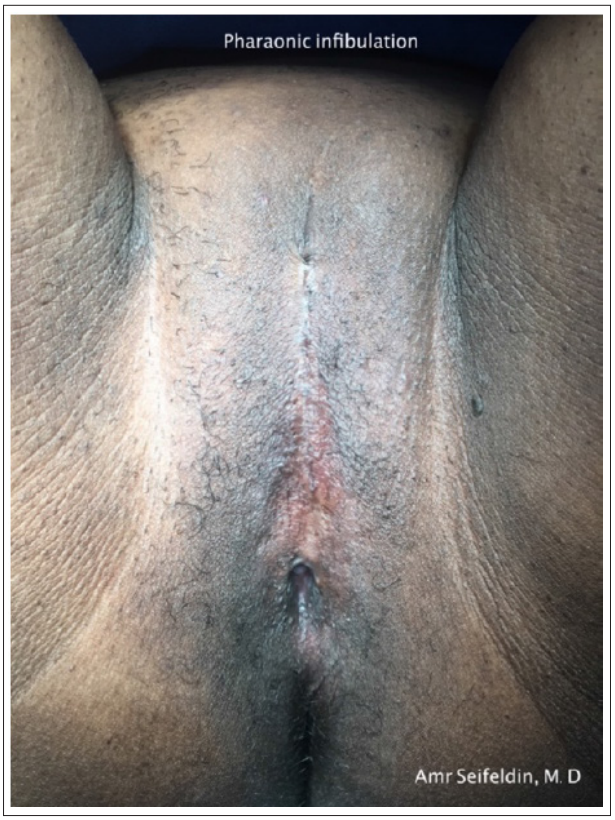

Figure 1a: Patient with complete infibulation

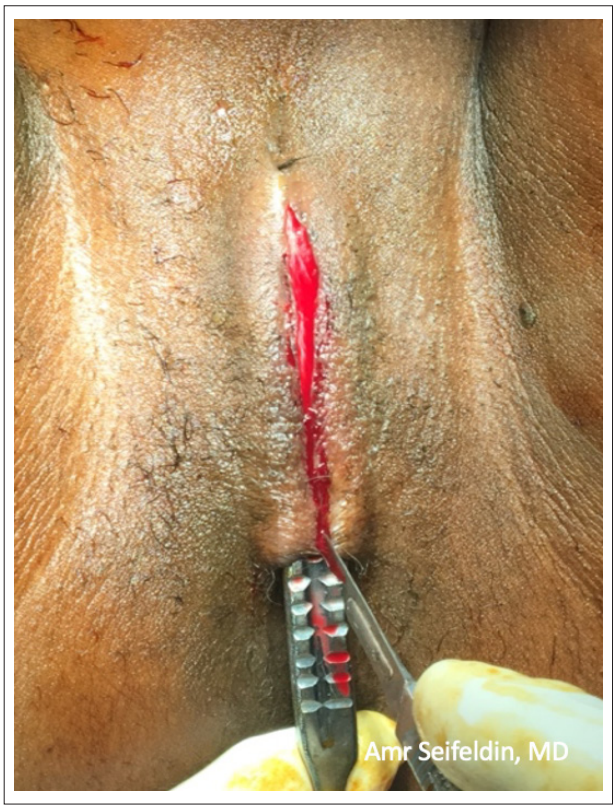

Figure 1b: Incision for defibulation

Figure 1c: defibulation with open vulvar wound (Seifeldin method)

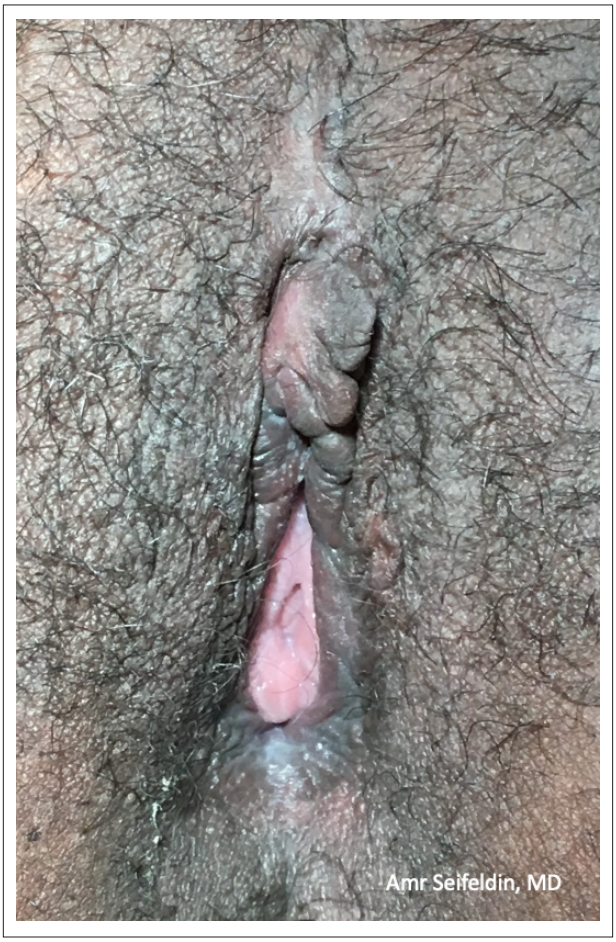

Figure 1d: 16 weeks after defibulation, clitoroplasty, and clitoral hood reconstruction

For individuals experiencing decreased clitoral sensitivity, clitoral reconstructive surgeries are occasionally considered [9-10] While different techniques of clitoral surgeries have been documented, they typically involve the removal of adhesions and scar tissue attached to the body of the clitoris, cutting of the suspensory ligament, and repositioning the clitoral body to the area corresponding to the original anatomical position of the excised glans clitoris [12]. Due to limited research on longitudinal efficacy and safety, clitoral reconstructive surgery is not currently considered a first-line intervention for those who have undergone FGM/C.

Labiaplasty

Labiaplasty is the most sought-after aesthetic genital procedure for women, with curvilinear and wedge resections being the most common techniques [13,14]. In regions such as Europe, the Middle East, and Asia, many women prefer a labia minora reduction to the level of or slightly above the labia majora [13,14]. In California, some women choose the Barbie Look Labiaplasty, a more aggressive curvilinear approach that removes most of the labia minora for increased comfort and to minimize its outline in swimsuits and leotards, achieving a smooth, "clamshell" and sleek look [13,14]. It was impossible to achieve this look with the standard plastic surgery wedge labiaplasties.

As demand grew, our labiaplasty techniques gained recognition through our teaching programs at the Alinsod Institute, WARAG Academy, and at international conferences, and were copied worldwide. Unfortunately, many surgeons without specialized training in vulvar anatomy attempted these procedures, leading to distressing outcomes. In particular, not knowing that the massive retraction of tissues in the upper third of the labia minora could result in the retraction of labial edges, ending up flat with partial or complete labia minora amputation (no labia at all) [15]. Several patients, referred to us in distress after total labia minora amputation and feeling they had parts of their vulva removed without their consent, sought revision surgery and repair.

Aesthetic concerns and genital self-image

Those who have undergone FGM/C or suffer from a botched labiaplasty surgery may express distress at the nonconsensual removal of parts of their genitalia or desire a sense of genital anatomic normalcy. The perception of one's genital appearance is termed "genital self-image" and encompasses feelings and thoughts about one's genital organs [16]. It is crucial to define genital selfimage as a distinct aesthetic preference unrelated to anatomy, medical conditions, or sexual function [17].

Substantial literature confirms the direct link between a woman's genital self-image and her sexual satisfaction [16,18]. Irrespective of gender or sexual orientation, individuals with a positive genital self-image are prone to higher sexual esteem, increased perceived sexual attractiveness, and, consequently, enhanced sexual satisfaction and function during intimate experiences [17]. Numerous studies underline the predictive nature of a woman's body perception on her overall sexual experience [20,21]. Likewise, positive genital self-image has been found to have a negative correlation with sexual distress and depression while positively correlating with sexual desire [20]. Labiaplasty techniques became well known through our teaching programs at the Alinsod institute, WARAG Academy, the media, our presentations in conferences, copied worldwide and attempted by untrained surgeons.

Recognizing the established importance of a woman's genital self-image, selecting the appropriate treatment for individuals with low genital self-image becomes crucial. Although psychosexual support is the primary approach for those to whom it is applicable, surgical intervention is also a viable option for those who desire it and for whom it is deemed suitable. Notably, aesthetic concerns motivate 52-87% of general aesthetic genital surgeries, while low selfesteem/ confidence accounts for 46% [17]. The literature consistently suggests positive patientreported outcomes from these surgeries, leading to a marked improvement in self-esteem and a significant reduction in negative genital self-image [17]. This affirmation is echoed in various studies, including the largest prospective study to date with a two-year follow-up conducted by five plastic surgeons in the United States [18]. In this study, women opting for and completing genital aesthetic surgery initially exhibited negative genital self-image compared to the control group. However, within six months post-surgery, parity between the groups was achieved and maintained over two years, supporting the notion that these surgeries contribute to an improved genital self-image [18].

It's worth noting, however, that studies differ in their findings regarding the impact on psychological well-being. While a prospective study from Australia observed a positive effect on genital self-image, no significant impact on patients' psychological well-being was found [22]. In contrast, a cross-sectional study from Saudi Arabia reported an increase in psychological wellbeing by 40-50% following the surgeries [23]Further exploration of the cultural context surrounding genital self-image, genital aesthetic surgery, and psychological impact is therefore needed.

Labia minora anatomy, function, & reconstruction

The labia minora are a pair of small cutaneous folds originating at the clitoris and extending downwards. The anterior folds encircle the clitoris, creating the clitoral hood and the frenulum of the clitoris. Moving obliquely and downwards, the labia minora form the borders of the vulva vestibule. Eventually, the posterior ends connect through the frenulum of the labia minora. They encircle the vulva vestibule, terminating between the labia majora. During sexual arousal, the labia minora become engorged with blood [24]. Alongside its role in arousal, the labia minora functionally serve to direct the stream of urine and safeguard the urethral meatus and vaginal opening. Therefore, the absence of the labia minora can lead to vaginal dryness and disruption in guiding urinary flow [25].

Currently, the published techniques involving the creation of entire new labia minora entail using flaps from the clitoral hood for reconstruction [25-27]. Nevertheless, for individuals affected by FGM/C or botched labiaplasty who want a labia minora wider than a few millimeters, the clitoral hood flap approach is often unfeasible due to the partial or complete amputation of the clitoral hood in FGM/C or surgery. Consequently, individuals distressed by the removal of their labia minora, whether due to FGM/C or botched labiaplasty, and who report negative genital selfimage are viable candidates for labia minora reconstruction.

One pioneering technique addressing labia minora reconstruction is the "grooving" technique described by Dr. Red Alinsod in 2007 [14,28]. This technique caters to those with botched labiaplasty or patients with prior 'Barbie look labiaplasty' who subsequently desire labial extension. A groove is created between the labia minora and labia majora with the inter-labial fold undermined medially, creating an optical illusion of a new labia when in reality it creates a groove [14].

It is precisely for patients with FGM/C or botched labiaplasty that Dr. Amr Seifeldin developed a labia majora flap technique in 2015. This technique involves marking, dissecting, and reflecting a labia majora flap upwards, thus creating a 1.5-2 cm wide labia minora. He presented his technique at several international conferences and workshops worldwide.

Methods

Patient Presentation

The women selected for this study had a history of either FGM/C or botched labiaplasty and expressed interest in aesthetic genital surgery. They sought consultations at Restore Multidisciplinary Clinic in Cairo, Egypt, or the Alinsod Institute for Aesthetic Vaginal Surgery in California and Texas, USA. Participants came from Egypt, Saudi Arabia, Sudan, Sweden, Canada, and the USA, all sharing the common complaint of amputated labia minora and a collective experience of type II FGM/C or botched labiaplasty.

All women articulated dissatisfaction with the appearance of their genitalia, leading to a notable impact on their self-esteem. Additionally, some reported experiencing vaginal dryness as an accompanying concern. To address these issues, each patient was offered psychosexual support alongside detailed medical consultation. After a thorough assessment, labia minora reconstruction emerged as the optimal treatment, addressing their cosmetic and functional concerns. To enhance their understanding, each woman was presented with photographs of previous patients who underwent the procedure, providing insights into the anticipated outcomes and a detailed briefing on post-operative care. Furthermore, potential complications associated with the procedure were discussed in depth with each patient.

Patient Characteristics

All pertinent patient data, encompassing a comprehensive history of FGM/C and botched labiaplasty, was systematically gathered. All women in the study had undergone partial or total amputation of the clitoral hood, making them suitable candidates for the presented techniques for labia minora reconstruction. Detailed patient characteristics for the Seifeldin and Alinsod techniques are demonstrated in Tables 1 and 2.

Table 1: Patient Characteristics

Case Number	Age at presentation	Age of circumcision	Relationship status	Additional history	Have you orgasmed before?	Physical Exam	Pre-Op image
1	27	10	single	Additional complaint of vaginal dryness.	Yes	Clitoral hood partially amputated. Glans clitoris partially amputated, sensation over clitoris intact. Labia minora bilaterally amputated.	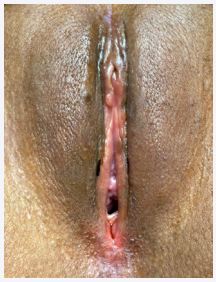
2	32	11	single	History of PCOS	no	Clitoral hood amputated. Glans clitoris amputated. Labia minora amputated bilaterally with small remnants.	Some pre-surgical markings present.

3	37	9	Engaged	Recently had polyps removed from uterus, were found to be benign. Additional complaint of vaginal dryness.	Unsure	Clitoral hood mostly amputated. Glans clitoris amputated, sensation over clitoris intact. Absent labia minora. Tiny remnant of left labia minora, remaining inferiorly.	
4	37	12	divorced		Yes	Clitoral hood partially amputated. Right clitoral hood lateral extension of clitoral hood present. Glans clitoris partially amputated, sensation intact. Multiple painful skin tags present near clitoris. Left labia minora completely amputated, right labia minora present with some fenestrations, is adhered to labia majora.	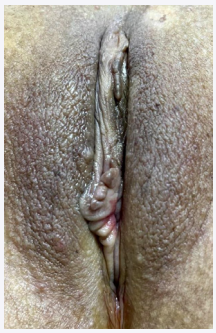

Table 2: Patient characteristics for Alinsod 'Grooving' technique

Age at presentation	Relationship status	Time since labiaplasty	Presenting concern	Pre-op image
21	single	6 weeks	Patient requested a Barbie Labiaplasty, then asked to extend her labia minora.	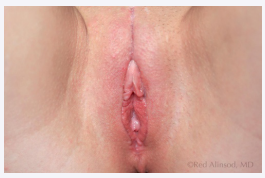

Surgical techniques & results

1. "Seifeldin technique": Labia Majora Flap for FGM/C & Botched Labiaplasty

- Mark the hairless aspect of the labia majora to outline the new labia minora flap.
- Consideration must be given to the overall size of the vulva and adjacent structures, as well as the patient's desires, to ensure the new design is both aesthetically and functionally proportionate.
- Based on surgical experience, the upper third of the flap tends to exhibit more retraction during healing, necessitating wider markings in this region.
- Graft thickness is about three millimeters thick and 1.5 - 2 centimeters wide.
- Administer local anesthesia medially and along the marked flap borders using Lidocaine and Epinephrine 1:200,000.
- Make an incision using a RF device or scalpel along the marked lines at a 30-degree angle, going deeper than the skin (approx. 3 mm) to include a minimal layer of subcutaneous tissue, providing the flap with stability and subtle volume.
- RRelease labia majora skin flap from the underlying tissue.
- Use cautery conservatively, to manage bleeding and induce slight fatty tissue shrinkage.
- Using scissors, partially release the labia majora skin laterally overlying the fat pad.
- Medially advance the released labia majora skin to cover the defect.
- Using 3-0 vicryl, suture in a pleated fashion to the superficial subcutaneous tissue at the base of the new labia minora, avoiding injury to the flap blood vessels in the crease.
- The average time of the procedure is one hour.
- Begin post-operative care immediately; the patient can return home on the day of the procedure.

Figure 2: case 1

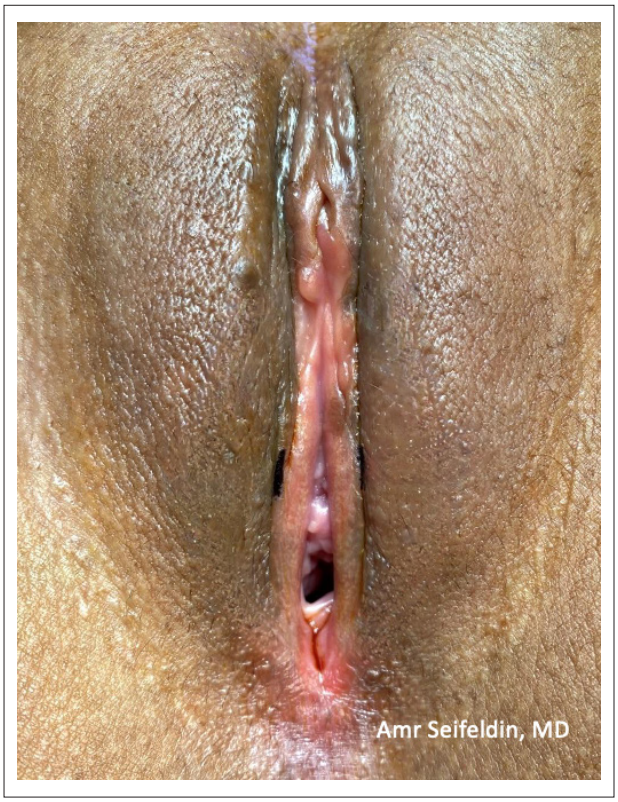

Figure 2a: case 1, bilateral labia minora amputation

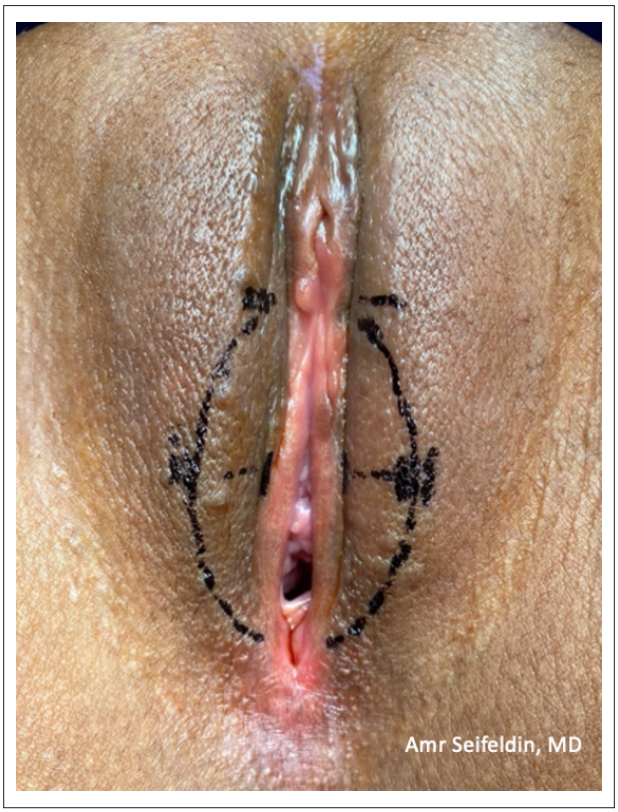

Figure 2b: with surgical markings

Figure 2c: post-op

Figure 2d: six weeks post-op

Figure 3: Case 2

Figure 3a: case 2, bilateral labia minora amputation

Figure 3b: with surgical markings

Figure 3c: Immediately post-op

Figure 4: Case 3

Figure 4a: case 3, bilateral labia minora amputation

Figure 4b: immediately post-op

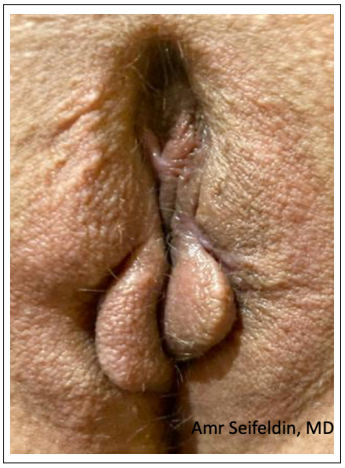

Figure 4c: 6 weeks post-op

Figure 5: Case 4

Figure 4a: case 4, unilateral labia minora amputation

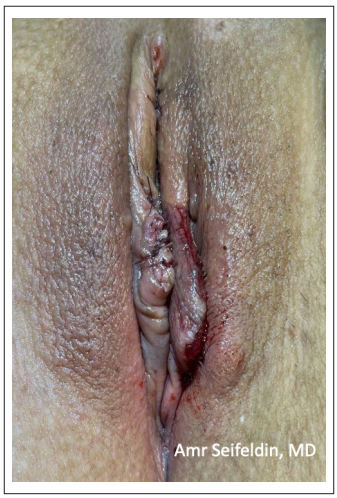

Figure 4b: immediately post-op

Figure 4c: 6 weeks post-op

2. ***Grooving "Alinsod Technique": for Botched Labiaplasty***

- Under local anesthesia, use radiosurgery to create a "groove" between the labia minora and labia majora, where the crease used to be, the former intralabial fold.
- Use the fine pinpoint "hair tip" of the RF to outline and incise from the top of the labia minora to the introitus.
- Use this "hair tip" to smoothen any labial and clitoral hood areas from the clitoral hood, frenulum and the labia minora.
- Use the small ball tip to continue the grooving deeper while maintaining hemostasis to create a flab of labia minora medially. With adequate numbing cream, a Q Tip is used twice daily to keep the edges from fusing together. This is performed for 4-6 weeks. No suturing needed.
- Suturing is sometimes used to attach the majora edge of the incision to minora to keep the appearance of a new labia minora.
- Injection of PRP into the surgical site and use Estrogen Cream or Exosome Cream to aid in healing for the next 6 to 8 weeks is recommended.

Figure 6a: Pre-op Labiaplasty

Figure 6b: 6 weeks Post-op Labiaplasty

Figure 8c: After Grooving (Alinsod Technique).

Figure 6d: 16 weeks Post-op

Post-operative care

Following the procedure, patients are advised to apply ice intermittently every waking hour for 20 minutes at a time during the 5-7 days to minimize swelling. Daily care involves cleansing the neo-labia minora with a betadine antiseptic solution and applying antiseptic/antibiotic cream or ointment to the raw dorsal surfaces to prevent infection. Patients are instructed to gently manipulate the neo-labia minora medially and laterally several times daily to avoid re-adhesion to the labia majora. This regimen is to be maintained for two weeks, with a transition to the exclusive application of the cream/ointment on the raw surfaces until re-epithelization, typically occurring within six to eight weeks.

While not performed in these cases, expedited healing can be encouraged by treating the posterior aspect of the neo-labia minora with an amniotic membrane graft or estrogen cream. Ensure that the rough side of the graft faces the dorsal labial fascia and administer multiple daily sprays of amniotic fluid. The amniotic fluid and membrane graft contains ample growth factors and cytokines, fostering accelerated healing. Additionally, consider the utilization of a growth factor-enriched recovery serum, such as AQ solutions from the United States, to augment the effectiveness of the healing process.

Follow-up

Patients were seen for follow-up appointments at approximately two weeks and eight weeks post-surgery. Only two were able to attend a six-month follow-up. Each patient received the clinic's phone number and was instructed to contact the clinic with any concerns.

Results

Labia minora reconstruction using the Seifeldin technique or the Alinsod technique was performed on patients undergoing bilateral and unilateral reconstruction. In all cases, healing occurred within the expected six to eight weeks post-procedure. None of the patients reported smoking cigarettes or consuming alcohol, factors that could impede the healing process. Ultimately, all patients were highly satisfied with the aesthetics of their neo-labia minora. They consistently expressed heightened self-esteem, using phrases such as "feeling complete" and "feeling confident" after the procedure. Noteworthy improvements were reported in the two cases that had endorsed vaginal dryness before the procedure, with all noting an enhancement in vaginal lubrication postoperatively.

Complications and Limitations

No intraoperative complications were observed. Postoperatively, minor complications were reported. All patients reported minimal pain and discomfort within the initial two to four days post-procedure, effectively managed with oral analgesics and intermittent application of cold compresses. In two instances, there was minor vulvar swelling within the first week post-op, which was promptly resolved with the application of additional cold compresses.

One patient experienced a minor adhesion involving the superior and inferior aspects of the raw surface of the neo-labia minora. This was attributed to insufficient application of antiseptic cream in the postoperative care phase. During the two-week follow-up, the adhesion was easily released with minor manipulation, leading to the subsequent successful healing of the neo-labia minora.

All patients consented to pre- and post-operative photography. Only two cases were able to attend the six-month follow-up due to residing far away from the clinic. While comprehensive longitudinal follow-up is preferred for all participants undergoing the procedure, logistical constraints prevented several patients from returning for additional check-ups, particularly those residing at a considerable distance from the clinic. Moreover, owing to the sensitive nature of genital surgery, photographs of each case's vulva were not captured at every visit, resulting in a lack of photos for a few cases after substantial healing.

Regrettably, the Arabic Female Genital Self-Image Scale (AVFGSIS) was not administered to the presented patients in Cairo; hence, this study lacks quantitative measurements of the cases' genital self-image before and after treatment.

Discussion

The described surgical procedures introduce an innovative approach to reconstructing the labia minora using a labia majora flap. This technique is particularly significant for individuals who have undergone FGM/C or have experienced complications from a previous labiaplasty, offering a means of restoring both aesthetic appearance and partial functionality. All of our cases expressed verbal satisfaction with their final results, reporting a subjective improvement in their confidence, self-image, and overall well-being.

Notably, the only published method for labia minora reconstruction to date involves the use of a clitoral hood flap [25]. The proposed surgical techniques, pioneered by Dr. Red Alinsod in 2007 and Dr. Amr Seifeldin in 2015, offer an alternative approach for individuals unable to undergo reconstruction through use of the clitoral hood. This is particularly useful in cases of FGM/C where the clitoral hood has been removed or in botched labiaplasties where the clitoral hood is too small to create a viable flap.

The paucity of available surgical techniques underscores the pressing issue of limited and under-researched treatment options for individuals who have undergone FGM/C or botched labiaplasty. Presently, available treatments for FGM/C are primarily directed towards either functional aspects, such as defibulation and clitoral reconstructive surgery, or psychosexual health through therapy. While these interventions are valuable, they do not adequately address a significant concern expressed by some individuals with FGM/C: distress related to the altered appearance of their genitalia due to nonconsensual vulvar tissue removal. While acknowledging the importance of addressing both functional and psychological well-being within a holistic, multidisciplinary approach, it is crucial to recognize the profound impact of genital self-image. Recognizing the importance of patient autonomy and empowerment, it is imperative to provide individuals with the agency to choose the most suitable approach for addressing their complications, including the option of aesthetic surgery.

The question naturally arises: what sets apart female genital cosmetic surgery (FGCS), encompassing procedures like cosmetic labiaplasties or clitoral reduction surgeries, from female genital mutilation/cutting? According to the WHO's definition of FGM/C, which involves the nonmedical removal of parts of the genitalia, FGM/C and FGCS are ostensibly indistinguishable [29]. However, the former is stigmatized with the label 'mutilation,' a term not applied to FGCS, which is more familiar in Western cultures [30]. This discrepancy challenges the ethnocentric perspective inherent in definitions by entities such as the WHO or international laws, which universally categorize FGM/C and FGCS as a single entity [31]. The pivotal distinction lies in the element of consent. While a minor cannot provide assent to the non-medical alteration of their genitalia (FGM/C), a competent adult has the capacity for informed consent in the context of FGCS. Although this differentiation warrants comprehensive ethical and moral scrutiny, acknowledging the role of consent is paramount. Much like women who have not undergone FGM/C have choices to modify the aesthetics of their genitalia through more Western surgical procedures, it is equally imperative to extend this viable option to women who have experienced FGM/C.

Equally crucial is the thorough anatomical education of physicians conducting FGCS. Unfortunately, despite many textbooks providing detailed coverage of female genital anatomy, only a few include comprehensive information on the anatomy of the clitoris, particularly the dorsal clitoral nerve. Remarkably, the inclusion of nerve and vasculature anatomy within the clitoris was only introduced into OB/GYN textbooks in 2019 [32]. Without proper training and education on clitoral and vulvar anatomy, physicians run the risk of causing harm to patients undergoing genital surgery, as we have frequently observed in our clinic with botched labiaplasties.

In the broader context, there is an imperative to explore additional therapeutic modalities as alternative interventions for diverse complications and concerns arising from FGM/C. Patients necessitate a comprehensive and multidisciplinary approach to address their issues, recognizing that the repercussions of FGM/C extend beyond the physical alterations to the genitalia. As researchers and healthcare providers, we bear a moral responsibility to develop and innovate methodologies to assist these individuals. It is crucial to conduct further quantitative studies to assess all interventions' longitudinal impact and efficacy, including labia minora reconstruction. Following the accumulation of sufficient evidence-based medicine, establishing a standardized protocol and treatment approach becomes feasible, aligning with the norm in various medical domains. Survivors of FGM/C warrant a comparable level of academic inquiry and

pursuit, and our dedication to this endeavor contributes to a more comprehensive and compassionate healthcare landscape.

Acknowledgments: None

Declaration of AI and AI-assisted technologies in the writing process

While preparing this work, the authors used Chat GPT to correct grammatical mistakes. After using this tool, the authors reviewed and edited the content as needed and take full responsibility for the publication's content.

Conflict of interest statement: none

Meetings where the technique has been presented:

9th Congress on Aesthetic Vaginal Surgery (USA, Oct. 2015). 1st World Congress on Aesthetic Gynecology (ESAG) (Italy, Apr. 2016). International Cosmetic Congress (Egypt, Aug. 2016). 10th World Congress on Cosmetic Gynecology (USA, Feb. 2017). ESAG (Spain, May 2017) ECAMS (France, Sep. 2017). American Academy of Aesthetic Medicine (USA, Nov. 2017). 3rd Congress on Aesthetic Gynecology (Poland, Apr. 2018). 2nd Congress on Cosmetic & reconstructive Gynecology (Turkey, Oct. 2018). International Cosmetic Gynecology Congress (ICGC) (UAE, Nov. 2018). Cosmetic Gynecology Workshop (UAE, Feb. 2019). Egyptian Society of Ob. & Gyn. (Egypt, Feb. 2019). Cosmetic Gynecology Symposium (Egypt, Apr. 2019). Cosmetic Gynecology Symposium (Pakistan, May 2019). Cosmetic Gynecology Workshop (Philippines, May 2019). Egyptian Society of Sexology (Egypt, Oct. 2019). Cosmetology & Cosmetic Gynecology Congress (Turkey, Oct. 2019). 2nd ICGC (UAE, Nov. 2019). Cosmetic Gynecology Session Kasr Al Ani OB/Gyn conference (Egypt, Oct. 2020). Cosmetic Gynecology session Kasr Al Ani Ob/Gyn conference (Egypt, May 2021). 2nd Cosmetic Gynecology Congress (Egypt, June 2021). 4th ICGC (UAE, Nov. 2021). Aesthetic Gynecology Workshop (Philippines, Apr. 2022). World Regenerative, Functional & Aesthetic Gynecology Conference, (Rio De Janeiro, Brazil May 2022). Kasr El Ani Ob/Gyn conference (Egypt, Sep. 2022). WARAG Aesthetic Gynecology Cadaver workshop (Poland, Nov. 2022). 5th IAGC (UAE, Nov. 2022). SEA conference (Egypt, May 2023). Aesthetic Gynecology workshop (Philippines, May 2023). WARAG Aesthetic Gynecology Workshop (Morocco, June 2023). FGM online course (Nigeria, Feb. 2024). Aesthetic Gynecology Workshop (Manila Philippines March 2024). American Urology & Gynecology Conference (Dubai, UAE April 2024)

References

2. Equality Now. FGM: A Global Picture. https://equalitynow.org/fgm-a-global-picture/. 2024.
3. United Nations: Gender equality and women's empowerment. Sustainable development goals. https://www.un.org/sustainabledevelopment/gender-equality/. 2024.
4. United Nations Children's Fund, Female Genital Mutilation: A Global Concern. 2024 Update. UNICEF, New York. 2024.
5. United Nations Children's Fund, Female Genital Mutilation in the Middle East and North Africa, UNICEF, New York. 2020.
6. World Health Organization. Sexual and Reproductive Health and Research. https://www.who.int/teams/sexual-and-reproductive-health-and-research-(srh)/areas-of-work/female-genital-mutilation/types-of-female-genital-mutilation. 2024
7. Farouki L, El-Dirani Z, Abdulrahim S, Akl C, Akik C, et al. The global prevalence of female genital mutilation/cutting: A systematic review and meta-analysis of national, regional, facility, and school-based studies. PLoS Med. 2022. 19: e1004061.
8. Young J, Nour NM, Macauley RC. Diagnosis, Management, and Treatment of Female Genital Mutilation or Cutting in Girls Pediatrics. 2020. 146: e20201012.
9. Seifeldin A. Genital restorative surgery after female genital Cutting. MOJ Womens Health. 2018. 7: 176-179.
10. Seifeldin A. Genital reconstructive surgery after female genital mutilation. Obstet Gynecol Int J. 2016. 4: 00129.
11. Sigurjonson H. Addressing Female Genital Mutilation/Cutting (FGM/C) in the Eraof Clitoral Reconstruction: Plastic Surgery Sexual Hearth. Current Sexual Health Reports. 2018. 10: 50-56.
12. Seifeldin A. Clitoral Reconstructive Surgery after Female Genital Mutilation the PMFA Journal. 2018.5: 1-2.
13. Abdulcadir J, Rodriguez MI, Say L. A systematic review of the evidence on clitoral reconstruction after female genital mutilation/cutting. Int J Gynaecol Obstet. 2015. 129: 93-97.
14. Elective female genital cosmetic surgery. ACOG.https://www.acog.org/clinical/clinical-guidance/committee-opinion/articles/2020/01/electivefemale-genital-cosmetic-surgery. 2024.
15. David Ghozland, Red Alinsod. Curvilinear Labiaplasty and Clitoral Hood Reduction Surgery; Clin Plastic Surg Published by Elsevier Inc. 2022. 455-471.
16. Xia Z, Zhang X, Kang Y, Chang G, Zhu L, et al. Barbie Deformity after Edge Labiaplasty: Classification and Repair Algorithm. Plast Reconstr Surg. Published online. 2024.
17. Rouzi AA, Berg RC, Alamoudi R, Alzaban F, Sehlo M. Female Genital Self-Image in Women with and Without Female Genital Mutilation/Cutting in Jeddah, Saudi Arabia. Sexual Medicine. 2020.8; 752-756.
18. Applebaum SA, Placik OJ. Genital Self-Image and Esthetic Genital Surgery. Clin Plast Surg. 2022. 49; 509-516.
19. Goodman MP, Placik OJ, Matlock DL. Evaluation of Body Image and Sexual Satisfaction in Women Undergoing Female Genital Plastic/Cosmetic Surgery. Aesthet Surg J. 2016. 36; 1048-1057.
20. Amos N, McCabe M. Positive Perceptions of Genital Appearance and Feeling Sexually Attractive: Is It a Matter of Sexual Esteem? Arch Sex Behav. 2016. 45: 1249-1258.
21. Berman L, Berman J, Miles M, Pollets D, Powell JA. Genital self-image as a component of sexual health: relationship between genital self-image, female sexual function, and quality of life measures. J Sex Marital Ther. 2003. 29: 11-21.
22. Abramowicz S, Oden S, Dietrich G, Marpeau L, Resch B. Anatomic, functional and identity results after clitoris transposition. J Gynecol Obstet Biol Reprod (Paris). 2016. 45; 963-971.
23. Sharp G, Tiggemann M, Mattiske J. Psychological Outcomes of Labiaplasty: A Prospective Study. Plast Reconstr Surg. 2016. 138; 1202-1209.
24. Al-Jumah MM, Al-Wailiy SK, Al-Badr A. Satisfaction Survey of Women After Cosmetic Genital Procedures: A Cross-Sectional Study from Saudi Arabia. Aesthetic Surgery Journal Open Forum. 2021. 3; 048.
25. StatPearls. Anatomy, Abdomen and Pelvis: Female External Genitalia https://www.ncbi.nlm.nih.gov/bo oks/NBK547703/. 2024.
26. Alter GJ. Labia minora reconstruction using clitoral hood flaps, wedge excisions, and YV advancement flaps. Plast Reconstr Surg. 2011. 127: 2356-2363.
27. Gress S. Labia Minora Repair. Aesthetic Plast Surg. 2021. 45: 2447-2463.

28. O'Dey DM, Kameh Khosh M, Boersch N. Anatomical Reconstruction following Female Genital Mutilation/Cutting (FGM/C). Plastic and Reconstructive Surgery. 2023. 10: 1097.
29. Red Alinsod. Radiofrequency and revision of Deepithelialized labia minora plasty, aesthetic gynecology surgery; ISPP. 2013.
30. Earp BD, Johnsdotter S. Current critiques of the WHO policy on female genital mutilation. Int J Impot Res. 2021. 33; 196-209.
31. Brussels Collaboration on Bodily Integrity. Medically Unnecessary Genital Cutting and the Rights of the Child: Moving Toward Consensus. Am J Bioeth. 2019. 19; 17-28.
32. Earp BD. Zero Tolerance for Genital Mutilation: a Review of Moral Justifications. Curr Sex Health Rep. 2020. 12; 276–288.
33. Handa, Lynn V, Van Le L. Te linde's operative gynecology (Twelfth). Wolters Kluwer, 2020.

Copyright: © 2024 Amr Seifledin, et al. This is an open-access article distributed under the terms of the Creative Commons Attribution License, which permits unrestricted use, distribution, and reproduction in any medium, provided the original author and source are credited.