

Health Education of New Mothers in Preventing Deepening of Hip-Femoral Dysplasia

Docente Elona Hasalla^{1*}, Ilda Taka², Brandi Fahriu³, Gerta Kaçani⁴, Blerta Hasalla⁵, Sulejman Baha⁵, Elda Ruçi⁶ and Irena Xhaferrri⁶

¹University of Elbasan Aleksander Xhuvani, Faculty of Medical and Technical Sciences Department of Preclinical Studies, Albania.

²University of Elbasan Aleksander Xhuvani, Department of Medical and Technical Specialties

³Faculty of Medical and Technical Sciences Tirana

⁴Faculty of Dental Medicine

⁵University of Florence Italy

⁶University of Elbasan Aleksander Xhuvani

*Corresponding author

Docente Elona Hasalla, University of Elbasan Aleksander Xhuvani, Faculty of Medical and Technical Sciences Department of Preclinical Studies, Albania.

Received: March 11, 2026; **Accepted:** March 18, 2026; **Published:** March 25, 2026

ABSTRACT

Developmental hip dysplasia (DHDD) is a congenital anomaly of the skeletal system, which affects the hip joint and can lead to permanent consequences if not diagnosed and treated in time. Despite advances in diagnosis and treatment, the main challenge remains early identification and intervention in the early stages of life.

This study aims to assess the importance of health education of new mothers in preventing the deepening of dysplasia and to analyse the effectiveness of conservative treatment with an abductor cushion. The study is based on a retrospective analysis of 68 cases of children diagnosed and treated for DHFK in the period 2018-2024. Factors such as age at diagnosis, gender, bilaterally of the pathology, as well as the effectiveness of treatment depending on the time of initiation of therapy were taken into account.

The results show that early treatment with an abductor pad is an effective method to prevent the deterioration of DHF and to ensure a healthy development of the coxofemoral joint. In the studied group, 60.3% of cases showed significant improvement, while only 13.2% required further treatment due to failure of conservative therapy. The study also highlights the importance of raising awareness among young mothers about the importance of early screening and the role of health personnel in the process of education and follow-up of children with this pathology.

In conclusion, this study suggests that early diagnosis and treatment of HFMD, supported by a well-structured health education program for new mothers, can minimize complications and significantly improve the quality of life of affected children. For this reason, it is recommended to strengthen the role of nursing personnel and promote health policies that support early identification and timely treatment of this anomaly.

Introduction

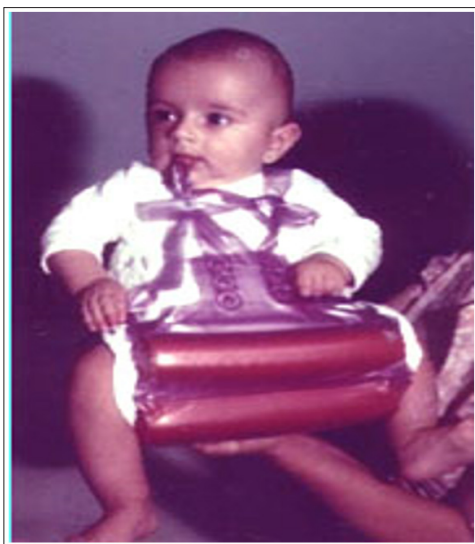Despite the great advances in the field of treatment of congenital hip and femoral luxation (CHL), this hereditary anomaly still remains a major challenge for new mothers and healthcare personnel; both as a problem in terms of early diagnosis for all medical systems and levels, and for the early initiation of treatment to have a successful final outcome.

In this topic that we are presenting at this annual scientific session at the Faculty of Medical and Technical Sciences; we thought of bringing our assessments, which in a way is also the

object and goal of the work of an employee in maternity, in the children's consultation or in other health systems, regarding the diagnosis and early initiation of treatment of this anomaly.

On the other hand, this objective is also related to the obligations of a pedagogue not only in the teaching process but also her efforts to sensitize new mothers and educate them on health in preventing the deepening of developmental hip dysplasia and why not also in starting treatment at the earliest possible age of this congenital anomaly with the "Abductor Pillow" [1].

Citation: Docente Elona Hasalla, Ilda Taka, Brandi Fahriu, Gerta Kaçani, Blerta Hasalla, et al. Health Education of New Mothers in Preventing Deepening of Hip-Femoral Dysplasia. *J Inten Care Emerg Med.* 2026. 2(1): 1-6. DOI: doi.org/10.61440/JICEM.2026.v2.14



A congenital anomaly of the type of developmental coxofemoral dysplasia immediately after the birth of the child may not be at the level of a fundamental disruption of the relationship of the femoral head to the acetabulum, or expressed in other words the presence or absence of the femoral head in the acetabulum, which is also the narrow meaning of the content of this term.

Developmental hip dysplasia is one of the most common and important human anomalies. It occurs in 1-1.5 cases out of 1000 live births. It is an anomaly that is not at all evident from the outside, absolutely hidden and silent, although diagnostic tests are known, even at the moment of the child's birth.

The idea of early treatment of L.K.K.F. with abductor devices is the gradual positioning or centering of the femoral head in its anatomical location, the acetabular fossa; and then the mutual relationships and influence on each other of the anatomical elements of the coxo-femoral articulation, will reform the latter [1,2].

Historical Moments and Scientific Findings of Developmental Hip-Femoral Dysplasia

Although since the time of Hippocrates, who first described it, in the complexity of this congenital anomaly, there are still different opinions regarding the etiology of the deformation, its pathogenesis, treatment and final results and even the very name of the anomaly. Peoples of color, blacks, Chinese, Japanese; generally, do not recognize this congenital anomaly. This fact has been evaluated as an indisputable argument and the deepening of scientific reasoning led to the conclusion that the fact was related to the customs of these peoples who raise their children by carrying them "saddle on their mothers' backs", or "supported on the iliac crests with their legs spread" (figure 1.1). With the evolution and deepening of thoughts, orthopedists and surgeons began to treat children with L.K.K.F. by placing and fixing the legs open and maintaining them in this position with various tools and systems, considering this position as protective and healing of this congenital anomaly [3].

In connection with the above findings, doctors began to devise and use devices and systems that kept the legs open, and the femoral head gradually positioned in its anatomical place. The need for the production and use of abductor devices is more or

less the putting into practice of logical ideas or wise conclusions accumulated over the years for the treatment of L.K.K.F. in young children [3,4].



Figure 1.1: This figure illustrates how a black mother holds her child in the position explained above.

The production of abductor devices was first described and used by Hilgenreiner in 1925, authors such as Forrester in 1933, Von Rosen. In our country, a commendable work has been done by Prof. Panajot Boga who devised and put into use the treatment of developmental coxofemoral dysplasia with the pneumatic abductor cushion, also known by the acronym japnab [4].

Object and Purpose

The problems of early diagnosis and treatment of D.ZH. K. as well as the crippling consequences for life from it, are individual and of varying degrees of difficulty. In this context, they constitute an important object of study not only in the treatment of this congenital anomaly at the nursing level but also in terms of the clinical training of neonatologists, midwives and health personnel who exercise their activity in clinics, nurses working in orthopedic clinics and wards in rural hospitals, etc. Our study aims to clarify some main issues that are listed below:

- To highlight the pathology of D.ZH. K, especially in terms of its early diagnosis (so widespread in our country), the early initiation of treatment at the nursing level as a possibility and reality with sufficient scientific knowledge.
- To draw the attention of new mothers and the control of their children with diagnostic tests for this pathology in the maternity ward, in the children's consultation room as well as in the orthopedic department of the "Xhaferr Kongoli" hospital in Elbasan.
- The earliest possible start of children with D.ZH. K with an abductor cushion as an efficient and effective method in the treatment of this congenital anomaly.
- Presentation of the results of the treatment as well as our modest experience in this regard.

Material and Method of the Work

In this modest study where we studied the charts of children with developmental coxofemoral dysplasia, children presented

for consultation and treatment from September 2018 to January 2024 were taken into consideration. 68 children were studied and treated. Of these children, 56% (38) of the entire series were bilateral and only 44% (30) of them were unilateral. So in total, 106 articulations with D.ZH.K. were treated.

Table 1: Distribution of Cases by Age and Gender

Age	Boys	Girls	Total
0-3 months	11	37	48
3-6 months	8	12	20
Total	19	49	68

The children for the period we are talking about, were treated and followed continuously by the authors of this paper. These patients were consulted, diagnosed and treated in “day treatment”, or with outpatient/day treatment, in the Day Surgery Department of the National University Orthopedics-Traumatology Service for the above-mentioned period and their follow-up is still ongoing by the author of the study at least within the first year of treatment.

Gender, Incidence, Laterality and Age of Treated Children

As can be seen from Table No. 1, the ratio of boys to girls in this anomaly is in the figures 1:2, or 1 boy to 2 girls. In the consulted literature, D.ZH.K. this ratio is the figures from 1:4 to 1:13 in favor of girls in 1000 live births. For our study group of 68 children the ratio 1:2 is negligible since the number of children taken into consideration is small and cannot be subject to statistical analysis.

Diagnosis of Developmental Hip-Femoral Dysplasia

These are essential to be performed on all newborns by the neonatologist and should be recognized by all personnel working in the clinic [5].

Manual Examination of the Hip Joints

It is the main examination and main diagnostic method in D.ZH.K. Regardless of the historical developments of this diagnostic method, the interpretations and considerations for it, it is still irreplaceable. Manual examination of the hip joints is based on two very valid and absolutely accurate tests in terms of the reasoning behind why they are performed [6,7].

Ortolan’s Technique

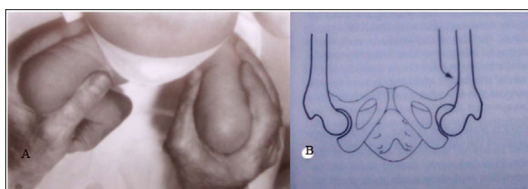


Figure 1.2: Methodology of Applying the Ortolani Test to a Newborn Child.

Source: Original Source

+

According to this technique, both hip joints are examined at the same time.

First, the hands are placed according to the photo and the thighs are abducted.

- Schematic representation of the exit of the femoral head

from the acetabulum when developmental dysplasia of the bone is present. The methodology of its execution is easy but requires attention and experience in its assessment. The child’s sides are flexed 90 degrees at the knees and hips.

- The hands are placed on the knees, the thumb on the medial side of the thighs and the other three fingers on its lateral side where the middle finger is on the greater trochanter.
- Then the thighs are abducted and with the middle finger placed on the greater trochanter, the femur is pushed medially.
- Schematic representation of the insertion of the femoral head into the acetabulum during his abduction.

In our study series of 68 cases, we performed it in 16 children who presented to the clinic only 3-7 days after birth. These were high-risk children, 4 had a breech birth, 2 were born prematurely and 9 children had a history in their parents, 6 children were born by Cesarean section. The other children were not examined because they presented after the third week of birth. The Ortolani test is only assessable in the first three weeks [8-10].

Abduction Limitation

Assessment of the volume of movements in newborns, mainly of abduction, which is performed by the examiner with the knee and hip joints flexed at 90 degrees. In this position, the examiner performs the abductor movement in the hip joint, which in other words tends to meet the outer sides of the child’s thighs. The outer sides of the thighs of newborns very easily meet the mattress. Abduction limitation is a test that is often encountered in developmental hip dysplasia. It has been found positive in 80% of the studied series or in 55 of the cases [10,11,3].

Evaluation of the Length of the Inferior Limbs

In unilateral developmental dysplasia of the hip joint, measurement of the length of the sides is not always a reliable sign for detecting the anomaly. Care should be taken during the examination to ensure that the child’s body is fully leveled and the presence of shortening is noted at the knee level [11,12].

Presence of asymmetry of skin folds

In already complete and established dislocations, there is a very evident alteration or asymmetry of the skin folds of the child’s thighs. But in coxo-femoral D.ZH. K, this test is not always significant. However, it is evaluated in the early diagnosis of D.ZH.K. If you look closely at Figure 1.3, you will notice that the folds on the left side are deficient compared to those on the right side [11,13].

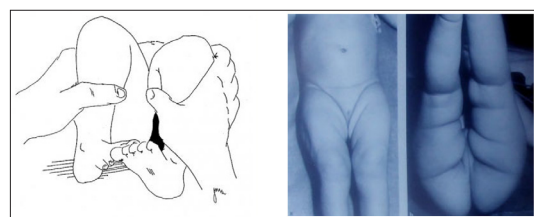


Figure 1.3: Assessment of the length of the sides and skin folds. Explanations in the text Regarding this diagnostic point, many authors, although they have found asymmetry of the folds, have identified D.ZH.K. in 36% of the 267 cases studied. In our series of 68 children up to the age of 12 months, these elements were found in 12 cases or in 17.6% of the entire series studied [14].

Radiological Data at the Nursing Level

The radiological examination of the coxofemoral joint is conditioned by the ossification of the femoral head. This phenomenon occurs in the fourth month after birth. In children with D.ZH.K., the ossification of the femoral head may be even more delayed. All children who presented for consultation at the orthopedic clinic were recommended to perform an anteroposterior radiograph of the pelvis. The radiographs are interpreted and evaluated based on the positioning of the nucleus of ossification of the femoral head or its centering in the acetabulum. In the radiological study of D.ZH.K., radiography in the anteroposterior projection is important. In this position, the relationships of the femoral head with the acetabulum, its centering in the lines, its coverage by the acetabulum, the ossification of the femoral head, etc. are studied [15,16].

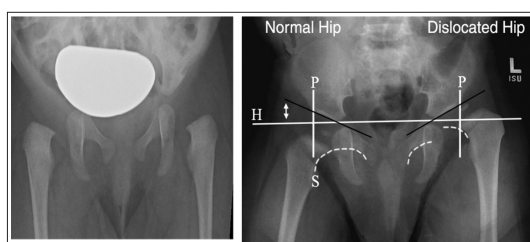


Figure 1.4: Radiograph of A 3-Month-Old Child Showing Radiological Signs Of D.Zhk.

Elements of radiological changes begin as early as 4-6 weeks after birth and include lateralization of the femoral neck in relation to the iliac bone, a slow and insufficient development of the acetabulum, and finally delays in the ossification of the femoral head. Although many signs and patterns of reading radiographs, especially anteroposterior ones, have been described [16,17].

Treatment of D.Zh.K With an Abductor Cushion

All children in our study were treated with the Plastic Abductor Cushion available on the market in three different sizes represented by the numbers 1, 2, and 3. The device was initially placed by the study author, assisted by qualified nurses from the consultation department [17].

The principle of selecting the number of cushions was based on the principle that the device should provide moderate abduction and be centered in the space between the two popliteal fossae [17].

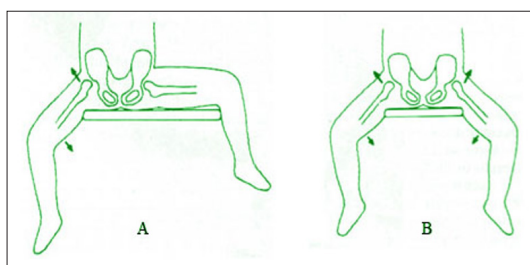


Figure 1.5: A- Possibilities of non-symmetrical placement of the cushion. Abduction is not performed symmetrically in both coxofemoral joints, resulting in a failure to gradually reposition the femoral head.

Parents were instructed on how to put on, remove, and provide sanitary care for the child, and efforts were made to explain the principle of treatment with this device, depending on their

cultural level, in order to overcome the unfounded fear that the joint could relax during these sanitary procedures [18].

The head centering check was performed on the first radiograph, usually in the second month after the start of treatment. The duration of treatment, although dependent on the interpretation of the radiological data on the centering of the femoral head, this treatment lasts at least 6-9 months to a year. Parents' contacts with the service are made every two months, and radiological checks were also requested every two months [19].

Evaluation and Results Achieved

The entire conservative treatment of this anomaly lasts for about 9 months. Correction is always possible, of course, respecting all stages of treatment, especially in terms of maintaining equal opening of the sides, gradually increasing the number of pillows, keeping them regularly, especially in the stages when the child needs to be changed or at times that are deemed necessary.

Table 2: Distribution of Treatment Results of D.ZH. K With Abductor Cushion.

child. still in treatment.	18 or 26.4 %
Child. failed.	9 or 13.2 %
Child. with good results.	22 or 32.5 %
Child. with very good results.	19 or 27,9 %
Total	68 or 100 %

In our series of 68 cases we have achieved these results, which are presented in Table :2. The nine children considered to have failed conservative treatment are scheduled for further treatment.

Criteria For Evaluating Results

In fact, outside the scope of this study, it is not at all easy to say when a dysplastic articulation will be considered healed. This word carries the weight of moral, ethical, social and legal implications if one of the following two errors is consumed.

To stop treating a child who is not yet cured or to treat a cured child in vain; for this reason we have tried to be very correct and scrupulous in the criteria for evaluating the results by referring precisely to our and foreign literature. As evidenced in Table 1, the children included in the study were divided into two groups depending on the age of the start of treatment; under three months and from three to six months.

The Centering of the Femoral Heads is Congruent with the Acetabulum

The created groups were studied to derive the results of the pillow treatment based on these indicators.

Centring of the Femoral Head in the Acetabulum

This element of the final result assessment was assessed in the control radiography. It is an important and valuable indicator in the successful completion of the treatment. In our study, this index is present in 41 cases or in 60.3% of the entire series, the rest are 9 children declared to have failed the treatment and 18 others who are still in unfinished treatment.

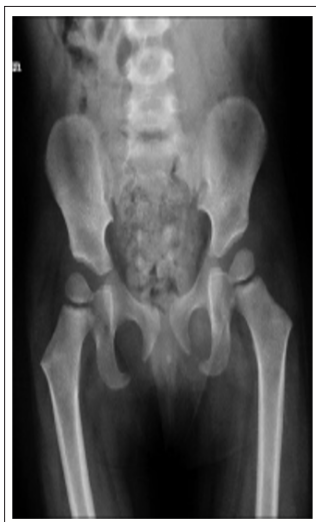

Figure 1.6: Graph one year after the start of the child's treatment

Improving the Acetabular Index

The acetabular index is the angle formed between the horizontal biacetabular line and the line connecting the center of the acetabulum with its outer edge. It is also called the AC angle and is a reliable indicator of acetabular slope.

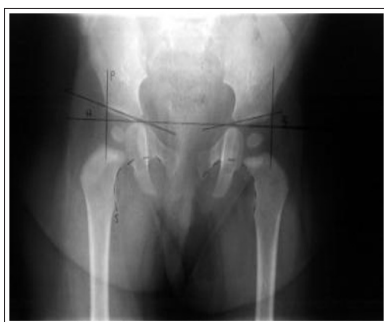

Figure 1.7: This graph shows the centering of the femoral head in the acetabulum and the normalization of the angle of the acetabular index.

This radiological parameter was evaluated at the end of the treatment. The evaluations in this index are also the same as those for the centering of the femoral head (7).

Conclusions

Developmental hip dysplasia is a congenital anomaly installed in the hip joint of the fetus during intrauterine life, invisible, but diagnosable immediately after birth. Despite the different opinions on the etiopathogenesis of the anomaly, hip dysplasia is treated with excellent results and without any consequences for the child who suffers from it.

- Coxo-femoral developmental dysplasia, converted into other words, means the disruption of the relationships of the bones participating in the formation of the coxo-femoral articulation, that is, of the femoral head and the acetabulum, and on the other hand contains the potential possibility of permanent luxation of the femoral head.
- Early diagnosis and initiation of conservative treatment even at the nursing level of this anomaly is the best "prophylaxis". This treatment is advisable to be done in the first days after the birth of the child.

- Correction of the anomaly of D.ZH.K. is done through positioning in adduction of the inferior extremities and maintaining them in this position for a period of 9-12 months. The methodology and procedures of the follow-up must be strictly respected.
- Conservative treatment of D.ZH. K is an advantage over other treatments of this pathology. It has excellent results and on the other hand is very well performed even at the nursing level.
- The cost element in conservative treatment is negligible and on the other hand we also remember the benefit that these children have from the state, which in one year reaches up to 500 euros.

Recommendations

- Early diagnosis and initiation of conservative treatment is the key and guarantee of successful treatment even at the nursing level of this congenital anomaly.
- The younger the child, the more adaptable the soft structures are, which have allowed the femoral head to luxate from the acetabular cavity, thus creating conditions for permanent disability for the rest of life.
- Find the opportunity and draw attention to the increase in nursing care for newborn children in terms of screening and diagnosing other congenital anomalies such as pes-equinovarus congenitalis, scoliosis.
- Getting rid of unfavorable habits of the development of the coxo-femoral articulation such as the hip joint in children. Understanding also by the popular masses that the hip joint is harmful and leads to the deepening of the D.ZHK.
- Increasing the competence and professional responsibility even at the nursing level, brings much higher results at work, in this context also in the diagnosis and early treatment of the D.ZHK.

Reference

1. Mazniku I. Clinical orthopedic. Book. 2006. 50: 112-136.
2. Kolb A, Schweiger N, Mailath-Pokorny M. Low incidence of early developmental dysplasia of the hip in universal ultrasonographic screening of newborns: Analysis and evaluation of risk factors. *International Orthopaedics*. 2016. 40: 123-127.
3. Guille JT, Pizzutillo PD, MacEwen GD. Developmental dysplasia of the hip from birth to six months. *Journal of the American Academy of Orthopaedic Surgeons*. 2000. 8: 232-242.
4. Padulo J, Oliva F, Frizziero A, Maffulli N. Basic principles and recommendations in clinical and field science research: 2016 update. *Muscles, Ligaments and Tendons Journal*. 2016. 6: 1-5.
5. Laplaza FJ, Root L. Femoral anteversion and neck-shaft angles in hip instability in cerebral palsy. *Journal of Pediatric Orthopaedics*. 1994. 14: 719-723.
6. Canham CD, Yen YM, Giordano BD. Does femoroacetabular impingement cause hip instability? A systematic review. *Arthroscopy*. 2016. 32: 203-208.
7. Larson C M, Stone R M, Grossi E F, Giveans M R, Cornelsen GD. Ehlers-Danlos syndrome: Arthroscopic management for extreme soft-tissue hip instability. *Arthroscopy*. 2015. 31: 2287-2294.

8. Ezoe M, Naito M, Inoue T. The prevalence of acetabular retroversion among various disorders of the hip. *Journal of Bone and Joint Surgery*. 2006. 88: 372-379.
9. Fujii M, Nakashima Y, Yamamoto T. Acetabular retroversion in developmental dysplasia of the hip. *Journal of Bone and Joint Surgery*. 2010. 92: 895-903.
10. Gala L, Clohisy JC, Beaulé PE. Hip dysplasia in the young adult. *Journal of Bone and Joint Surgery*. 2016. 98: 63-73.
11. Chadayammuri V, Garabekyan T, Bedi A. Passive hip range of motion predicts femoral torsion and acetabular version. *Journal of Bone and Joint Surgery*. 2016. 98: 127-134.
12. Garabekyan T, Ashwell Z, Chadayammuri V. Lateral acetabular coverage predicts the size of the hip labrum. *American Journal of Sports Medicine*. 2016. 44: 1582-1589.
13. Gupta A, Chandrasekaran S, Redmond JM. Does labral size correlate with degree of acetabular dysplasia? *Orthopaedic Journal of Sports Medicine*. 2015. 3: 2325967115572573.
14. Kim HT, Lee TH, Ahn TY, Jang JH. The fate of DDH hips showing cartilaginous or fibrous tissue-filled joint spaces following primary reduction. *Journal of Pediatric Orthopaedics*. 2015. 37: 84-191.
15. Tréquier C, Baud C, Ferry M. Irreducible developmental dysplasia of the hip due to acetabular roof cartilage hypertrophy: Diagnostic sonography in 15 hips. *Orthopaedics & Traumatology: Surgery & Research*. 2011. 97: 629-633.
16. Ashwell Z R, Flug J, Chadayammuri V, Pascual-Garrido C, Garabekyan T. Lateral acetabular coverage predicts femoroacetabular cartilage thickness. *In Review*. 2016. 3: 262-269.
17. Ross JR, Zaltz I, Nepple JJ, Schoenecker PL, Clohisy JC. Arthroscopic disease classification and interventions as an adjunct in the treatment of acetabular dysplasia. *American Journal of Sports Medicine*. 2011. 39: 72-78.
18. Martin RL, Palmer I, Martin HD. Ligamentum teres: A functional description and potential clinical relevance. *Knee Surgery, Sports Traumatology, Arthroscopy*. 2012. 20: 1209-1214.
19. Duplantier NL, McCulloch PC, Nho SJ, Mather RC III, Lewis BD, et al. Hip dislocation or subluxation after hip arthroscopy: A systematic review. *Arthroscopy*. 2016. 32: 1428-1434.