

## Guidelines on Photoepilation: Techniques for Intimate Body Areas

Godfrey Town<sup>1\*</sup>, Ross Martin<sup>2</sup>, Anita Clarkson-Dalton<sup>3</sup> and Samantha Hills<sup>4</sup>

<sup>1</sup>Senior Research Fellow, Department of Dermatology, Aalborg University Hospital, Aalborg, Denmark; RPA2000 Certificated Laser Protection Adviser; Registered Clinical Technologist, UK

<sup>2</sup>Expert Registered Healthcare Practitioner (ERHP), Expert Witness, UK

<sup>3</sup>Senior Assessor, Online Laser Training Ltd, UK

<sup>4</sup>Clinical Director, Lynton Lasers Ltd.; Honorary Lecturer, Division of Musculoskeletal and Dermatological Sciences, The University of Manchester, UK

### \*Corresponding author

Godfrey Town, Senior Research Fellow, Department of Dermatology, Aalborg University Hospital, Aalborg, Denmark Email: godfreytown@mac.com

Received: December 01, 2023; Accepted: December 21, 2023; Published: December 23, 2023

### ABSTRACT

General best practice guidelines for safe laser/IPL hair reduction have already been published in peer reviewed professional medical journals. The safe operation of a laser/IPL for hair reduction demands creation of a facility safety protocol, compliance with laser/IPL system set-up, designated client parameters and dosimetry. Compliance with national, regional and local regulations are equally applicable for hair removal prior to gender reassignment surgery. These guidelines briefly review the options for hair reduction and the mode of action of photoepilation but concentrate on classification of birth male and birth female intimate body areas and treatment procedure including planning prior to gender reassignment surgery. There is a dedicated review section on pilonidal sinus treatment procedure as well as delegation of photoepilation, adverse effects, safety precautions, pain control and client aftercare.

### Introduction

There has always been a demand for treatment of superfluous hair in the more intimate areas of the body [1-3]. Temporary methods of removing hair in this sensitive area have been achieved using sugaring, plucking, threading, razors, shavers, trimmers, epilators, depilatory creams, electrolysis, hot wax and cold strip wax methods, all of which can cause side effects such as hyperpigmentation, ingrown hair and folliculitis. Best practice general guidelines for safe laser hair reduction have already been published in peer reviewed professional medical journals [4]. There is growing popularity for home-use lasers and intense pulsed light (IPL) for use in accessible areas.

**Electrolysis** was the first hair removal treatment that was recognized as permanent by the US Food and Drug Administration (FDA) - regardless of hormonal, hereditary or metabolic factors. A weak electric current is conducted by a fine, sterile probe directly into the natural aperture of the hair follicle. There are three types of energy delivery - Galvanic, thermolysis and blend and the objective is to destroy the dermal papilla, the matrix, and the 'bulge' in the hair shaft, which are all responsible for regrowth of hair. Successful outcome of this treatment relies on the hair being in the anagen phase of the growing cycle when it is fully attached to the papilla and is also highly operator dependant [5].

**Light-based hair removal** uses photothermal energy to create sufficient heat in the hair follicle to damage the growth cells in and

around the follicle that cause hair re-growth. This is achieved by light absorption in the melanin of the hair shaft. This absorption and conduction of heat energy causes damage to the surrounding hair growth cells preventing the follicle from producing further hairs [6,7]. As there is also melanin in the epidermis (giving the skin its natural colour), care must be taken to select appropriate energy levels to induce the desired therapeutic outcome without damaging surrounding normal tissue. Darker skin, darker hair and greater hair density will require lower energy levels. Lighter skin, lighter hair and thinner hair density will require higher energy levels. White or vellus hair will be unaffected by light therapy treatment.

Electrolysis and light-based treatments such as laser and IPL are considered permanent hair reduction and successful photoepilation of intimate body areas has been reported [8]. However, there is no published clinical or procedural guidance for laser/IPL hair reduction technique in intimate body areas. As such treatments may affect the privacy and dignity of a cosmetic client, laser/IPL practitioners intending to undertake these procedures should establish clear protocols and best practice guidelines.

All clients should complete a thorough health history questionnaire and provide written informed consent to treatment. Clients need to understand the treatment procedures, the anticipated results and have realistic expectations of the likely outcomes. It is important to stress that once the hair has been successfully treated, any

future re-growth may be severely limited - cosmetic clients must consider whether they still want bare skin in intimate body areas when they are older.

### General Considerations

The safe operation of a laser/IPL for hair reduction demands creation of a facility safety protocol and compliance with laser/IPL system set-up, designated client parameters and dosimetry along with adherence to national, regional and local regulations [9].

Cosmetic laser hair reduction treatment is suitable for both birth female and birth male clients and includes any area that the client has unwanted hair but allowing for the fact that areas with more pigmentation and/or sensitivity will require less aggressive energy settings.

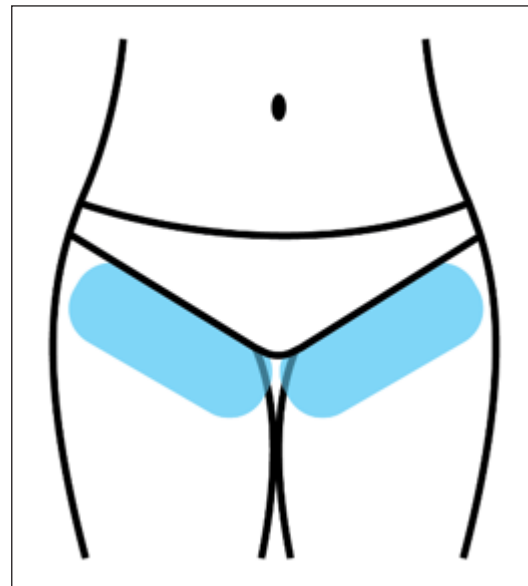
**Birth female gender** intimate body areas include:

- the upper bikini line - the area above the femoral triangle of Scarpa, and directly below the groin line of the bikini or underwear
- the extended bikini line - this area covers treatment over the mons pubis, labia majora and perineum
- the G-string - this area is the gluteal cleft around, but not over, the anus
- the nipple or areola.

**Birth male gender** intimate body areas to treat are similar but may include the scrotum and base of the penis. Birth males are increasingly choosing to remove hair in this area both for aesthetic and hygiene reasons but it is also important to be aware of the desire for hair removal in this area by clients who are preparing for surgical gender reassignment.

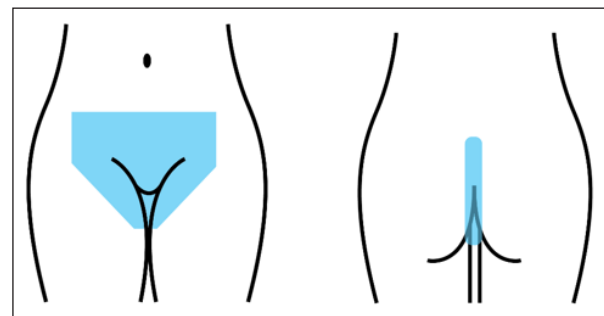
Before treatment is commenced, the precise area where hair removal is desired should be precisely defined. Clear communication with the client about their preferences and the specific areas that they want treated is essential, keeping in mind that definitions and the terminology used may vary between individuals. For example, in many clinics and salons, a 'Brazilian' will include the perineum and peri-anal area, and it's important to determine if that is what the client has in mind. Common terms and definitions are:

1. Standard Bikini Line - hair removal along the edges of the bikini or underwear line. The area with visible hair can extend some way down the thigh in some clients. One rule of thumb is to treat an area of approximately 1-2 finger widths inwards from the crease of the groin and 3-4 finger widths outwards from the most medial part of the inner thigh. Incorporating areas greater than this is sometime termed an 'extended bikini line' treatment. (Figure 1)
2. Brazilian - It typically includes the removal of hair from the front, back, and in between the buttocks, although not all clinics will include hair removal from the labia and perianal areas as standard. With a Brazilian, a small area of hair is left on the mons pubis (the top of the pubic bone). This is usually a strip of hair (i.e. a rectangular shape) but can be other shapes (such as a triangle) according the clients' preference. The size of the area that is left should be agreed with the client in advance.



**Figure 1:** Standard Bikini Line area for treatment

3. Hollywood or 'Integral' - Hollywood removal is similar to the Brazilian, but it involves the complete removal of all pubic hair from the entire bikini area, including the front, back, and in between the buttocks. (Figure 2) A high percentage of women and men, particularly those who are younger and more sexually active, prefer the complete removal of pubic hair [10].



**Figure 2:** Hollywood or 'Integral' area for treatment

Laser/IPL hair reduction on mucous membranes following surgical skin grafts (including the oral cavity, eyelids and the birth female labia minora) should only be performed by a medically qualified healthcare professional.

Therapists who provide treatments to intimate areas should first consider the following:

1. It is optional; if you do not wish to provide this treatment, do not do so.
2. Another member of staff may be present for additional personal security ('chaperone').
3. The environment needs to reflect the sensitivity of the treatment - clean, clinical and professional.
4. Wear clinic uniform and personal protective equipment (PPE) - examination gloves and laser face mask.
5. Ensure that any jewellery in the treatment area is removed prior to treatment to avoid reflecting or focusing energy elsewhere, which could be an eye hazard.
6. Do not book the client in for further treatments if there is any inappropriate or offensive behaviour.

- You may consider charging higher fees for intimate areas as this requires the additional costs of providing chaperones, completing Enhanced Disclosure and Barring Service (DBS) checks (or equivalent checks in devolved jurisdictions), extra eyewear for chaperones, etc.

Laser service providers delivering intimate body area treatments should ensure that all laser operators and any nominated staff acting as chaperones have completed enhanced DBS certificate checks or equivalent criminal record checks in other jurisdictions.

#### Treatment Preparation - Test Patch

Advise the client to attend their appointments having showered or bathed that day. Clients will be asked to remove clothing from the waist down so avoid wearing items such as jump suits or other restrictive clothing. Advise clients to wear light underwear and be prepared to provide white paper underwear if necessary. Depending on the area to be treated, underwear may need to be removed completely.

Once the assessment and treatment plan has been agreed, multiple patch tests should be carried out on different treatment areas. Take into consideration sensitivity and areas of different skin tone /pigmentation in some intimate body areas which can be other than the natural Fitzpatrick skin phototype would indicate. To ensure there is no adverse skin reaction, test patches should be carried out approximately 7 days before treatment.

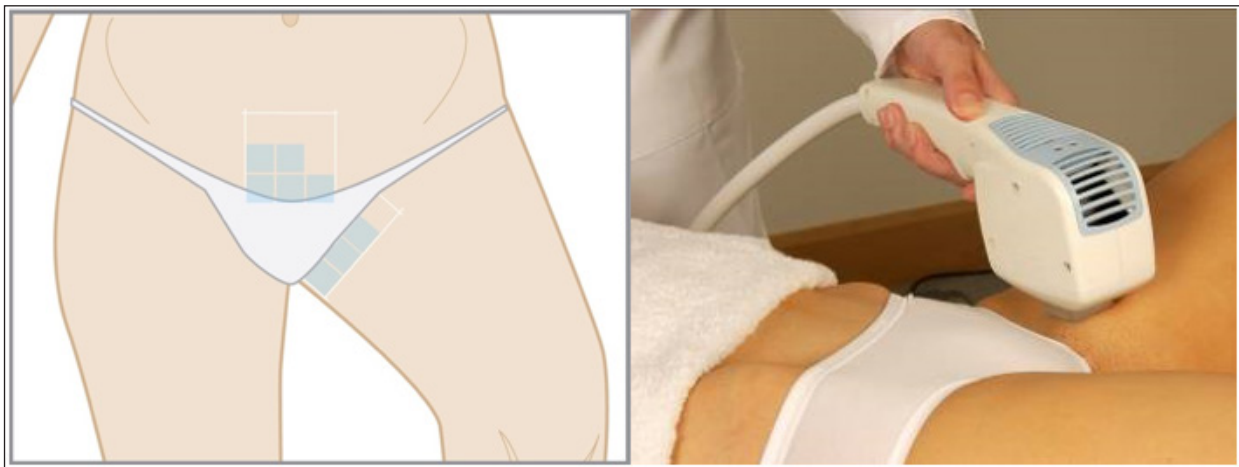Dark Fitzpatrick skin phototypes may require extending this waiting time to about 14 days before full treatment commences.

Where possible and with the client's written consent, to establish hair density a discreet photograph of a small area can be taken in a way that the client cannot be identified. Generally, underwear can be positioned in such a way that there is not any need to include the genitalia in clinical photographs used to assess treatment progression.

A treatment appointment should be given with the recommendation that the patient/client will shave the treatment area approximately 24 - 48 hours prior to that appointment. This is to ensure that the area is not sensitized, or the skin compromised immediately before the treatment is carried out. Don't ask the client to shave the gluteal cleft/peri-anal area as this could cause skin injury.

#### Treatment Procedure: Bikini Line

There are different procedure types: 'Bikini', 'Brazilian' and 'Integral' (i.e., "full clearance" or "Hollywood"). The simplest is the Bikini, which follows the line of the underwear. Therapists experienced in Brazilian and Integral waxing techniques will adopt these treatments with laser or IPL with ease as the body positioning to reach all required intimate areas is the same as for waxing (Figure 3). However, for therapists not familiar with waxing techniques the following guidance for laser/IPL is recommended.



**Figure 3:** Bikini line: Areas to be treated. The area should be marked in sections using a white makeup pencil as the tone of the skin may vary and adjustments in the laser/IPL fluence may be necessary.

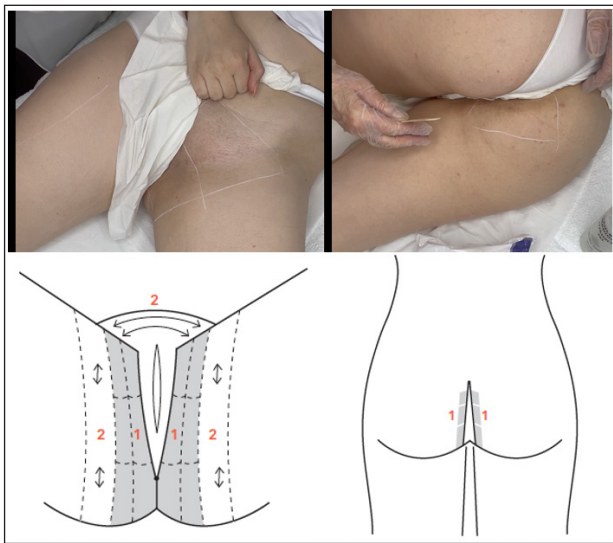
- Advise clients to wear light underwear and be prepared to provide white paper underwear if necessary. Depending on the area to be treated, underwear may need to be removed completely.
- Areas to be treated with laser/IPL should be shaved in advance of treatment with no more than 1 mm of stubble above the skin.
- On no account treat over dark-coloured underwear as it will absorb laser or IPL energy and may burn.
- Bikini line areas are considered to be moderate to high pain sensitivity areas [11]. Take great care with treatment. Cooling methods should be adopted as described below.
- Always respect the privacy and dignity of the client by covering intimate areas not being treated with towels or drapes.
- More cooling gel than normal should be applied to delicate areas to maximise client comfort.
- Post treatment cooling should be extended for delicate areas (forced-air, cooling gel packs, etc.).

#### Treatment Procedure: Brazilian/Hollywood

To ensure that the client has the least possible discomfort and the choice to stop and only treat for 'Brazilian' rather than 'Hollywood' if they find it too uncomfortable, start from the least sensitive and lightest area and work progressively inwards towards the most sensitive and darkest skin area. Use a progressively lower laser/IPL fluence if required.

The treatment area should be marked in sections using a white makeup pencil as the tone of the skin may vary and adjustments

in the fluence may be necessary. 'Zoning' the area will also assist in even placement of laser/IPL shots (Figure 4).



**Figure 4:** Inguinal/groin area marking. Perianal/perineal area marking in recovery position. Use towels or drapes for client privacy and dignity.

The scrotum and penis can be treated. When treating birth males or pre-operative trans women, it is suggested that the client is asked to move their penis or stretch the skin on the scrotum as and when required.

The supine (lying face upwards) body position is preferable for the bikini line and inguinal/groin areas (legs abducted/spread and flexed/bent as needed) with the buttocks raised off the couch using towels for easier treatment access and the recovery position for the perianal areas, as this maintains maximum dignity for the client. If treatment is performed with the client 'on all fours', unintentional natural bodily functions may occur during treatment (e.g. release of intestinal gases, which can be a fire hazard). The supine position avoids this risk and also minimises the risk of the client falling from the treatment couch. Moreover, with the larger client, it may not be possible to reach the treatment area successfully whilst in the 'on all fours' position.

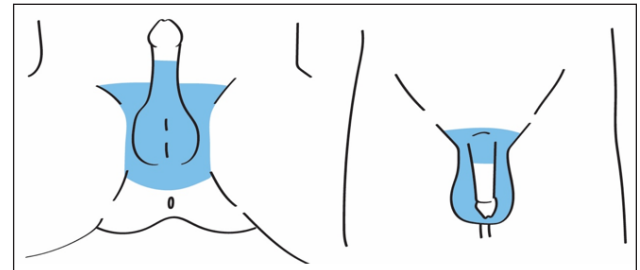
#### Treatment Procedure: Hair Removal Prior To Gender Reassignment Surgery

Laser hair removal is a common procedure for transgender clients seeking gender-affirming treatments. Removing hair from the genital and surrounding areas can be a crucial step in helping individuals feel more comfortable in their bodies and hair removal in this area is an essential step before birth male to female surgical reconstruction of the genitals. Laser hair removal pre-surgery has been shown to prevent complications such as folliculitis, hair balls, and dyspareunia. Permanent hair removal has also been shown to improve patient satisfaction with their postsurgical results [12].

For neovaginoplasty surgery, skin from the penile shaft and mid-scrotum is used to create the vaginal canal; therefore, all hair in this area should be removed so the internal vaginal walls and urethra remain hair-free. Hair within the neovagina can increase infection risk and encrustation of debris, whilst hair within a neourethra will obstruct urine outflow, promote urine retention

within the urethra, and often become encrusted, all of which increase the risk of urinary infections and post-void dribbling of urine.

All hair should be permanently removed from the scrotal sac and the penile shaft before surgery, including a 2.5 cm area around the base of the penis. Hair from the bottom of the scrotum to 2.5 cm above the anus in a 6 cm wide strip should also be removed [13] (Figure 5).

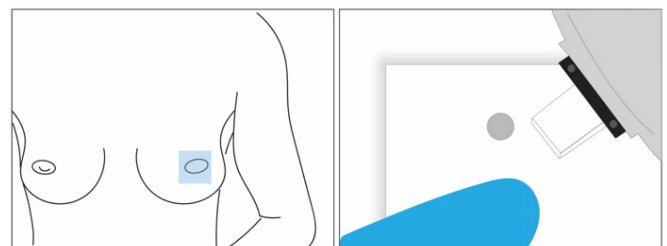


**Figure 5:** Anatomic borders of treatment area for permanent hair removal in preparation for neovaginoplasty. Treatment areas include scrotal skin, perineum, penile shaft and base of the penis.

Clients will need to be counselled that any white or grey hair in the area will not respond to laser treatment and may need to be permanently removed with electrolysis. It is recommended to wait a minimum of 3 months after the last laser hair removal treatment before proceeding with surgery. This will help to ensure that no further hair regrowth has occurred.

#### Treatment Procedure: Nipple/Areola Complex

Hair in the nipple area is usually located on and at the periphery of the areola and can be of concern to both birth females & birth males. Pigmentation must be considered and pulse duration and energy density (fluence) parameters adjusted accordingly to customise treatment. The nipple area is considered an area of moderate pain sensitivity [11]. Cooling methods should be adopted as described below.

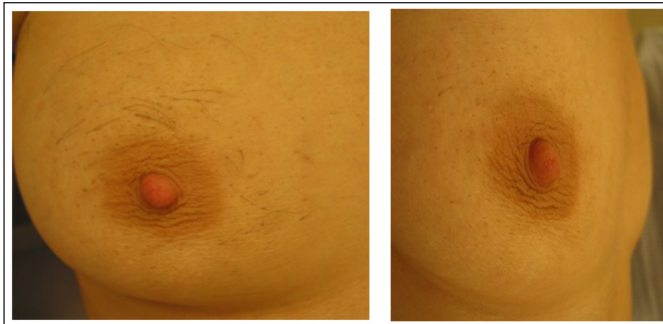


**Figure 6:** Hair treatment of the nipple/areola complex: Mask sensitive areas before treatment using a nipple shield, white cotton cloth cut-out, white adhesive label, damp cotton wool/gauze or card template (right).

Nipple/areola complex hair may be treated as follows:

1. Mask the central reddish/brown (areola) nipple area using a nipple shield, white cotton cloth cut-out, card template, white adhesive label or damp cotton wool/gauze (Figure 6).
2. For treatment over areola tissue, extreme care should be taken to consider the increased skin pigmentation where more energy will be absorbed. For example, a white card 'template' can be used with a small hole punched in the centre to allow spot treatment while masking surrounding sensitive skin areas.

3. With as much of the nipple as possible safely protected, the whole area may be treated in rows (over the protective masking) to ensure that all the hairs on and at the margin of the areola are treated.



**Figure 7:** Before after 6 laser treatments.

Hair on the nipple/areola complex before and after 6 laser treatments is shown in Figure 7.

**Specific Treatment of Pilonidal Sinus**

A pilonidal sinus is a pathological medical condition which can result in a chronic abscess and/or non-healing wound typically between the buttocks. The underlying cause is a blind-ending track leading from the skin, containing loose hairs. The hairs are usually derived from the patient, but in some cases, notably those acquired by barbers, the hairs are derived from the client [14]. The disease is commonest in the natal cleft, but has been described in the scalp, the prepuce and the groin [15,16]. A pilonidal cyst is believed to be an acquired condition caused by the presence of hair in involuted epithelial tissue in the natal cleft

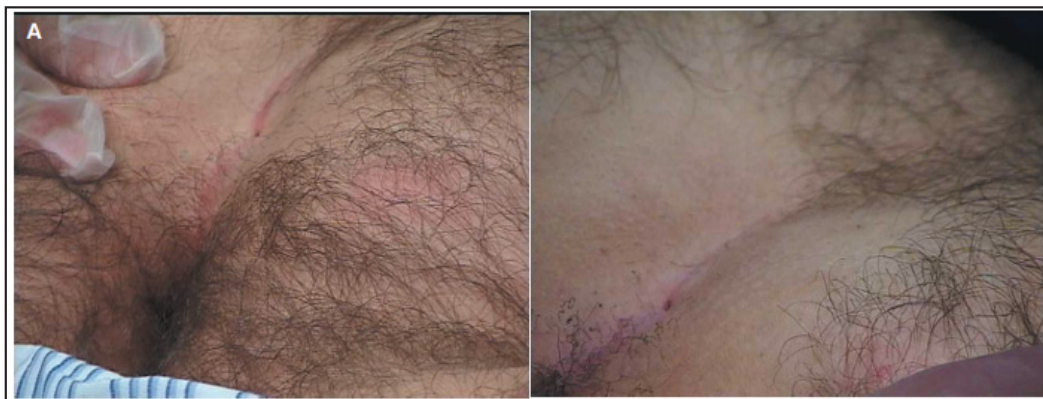with consequent irritation, inflammation and abscess formation. It is more common in men than women and occurs in the age group 15-40 years. It is very unusual after the age of 40 years. Medical management may reduce the severity of disease. Proper hygiene is paramount. Treatment of an active pilonidal sinus should only be undertaken by or in consultation with a physician.

Pilonidal sinus presents as a swelling, which may or may not be painful. The commonest complication is abscess formation. Previously, standard treatment was excision of all the inflamed tissue allowing the wound to heal by granulation, although this can be a very long, tedious process. More recently, treatments are becoming less invasive [17]. If a pilonidal sinus is small, then it may only require antibiotic treatment. If the sinus develops into an acutely inflamed abscess, then it will require drainage.

There are three alternative surgical treatments:

- the lesion can be incised and laid open
- the lesion can be completely excised
- the lesion can be curetted and injected with phenol

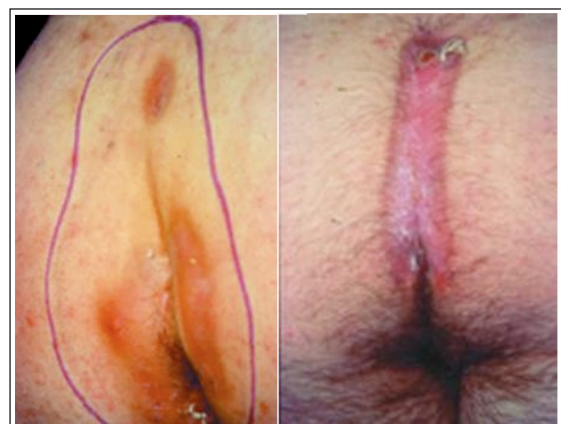However, surgical treatment of pilonidal sinus disease of the natal cleft has a significant failure rate and use of laser as a primary treatment or as an adjunct to surgery in refractive cases has been shown to be effective [18-25]. Light based treatment may also be used in preventing the growth of hairs into wounds that have been left open and allowed to granulate. The laser beam can reach difficult areas inaccessible with a conventional razor. Hair clearance in the natal cleft (deep groove between the buttocks) before and after seven laser treatments is shown in Figure 8.



**Figure 8:** Pre-treatment and 6 weeks post 7 laser treatments showing hair clearance in the natal cleft [20].

**Laser/IPL Treatment Procedure**

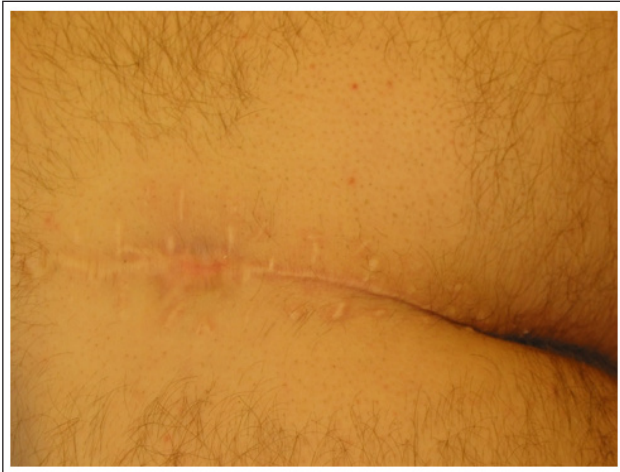
The peri-anal area is very sensitive and anaesthetic cream or injections of local anaesthetic can be helpful. Hair should be shaved or clipped in an area 4 to 5 cm around the problematic-sinus to reduce carbonisation of the hair follicles above the skin surface and consequent laser plume containing particulates and noxious gases. While pilonidal sinus can be treated successfully with intense pulsed light (IPL) [26,27] some skin contact diode laser and IPL applicators may be more difficult to position without significant retraction of the buttocks (Figure 9).



**Figure 9:** Natal cleft pre-treatment and 8 weeks post 1 treatment showing granulation and healing of tissue [28].

Post-treatment cool aloe vera gel may be applied to intact skin. In the case of an open granulating wound, antibiotic ointment might be preferred.

Treatments are performed at 6 to 8 week intervals for the first 3 to 4 treatments and then every 8 to 16 weeks until remission of infection and removal of most of the hair. Simultaneously, infectious folliculitis should progressively decrease in extent and intensity. An example of successful hair clearance after 11 laser treatments is shown in Figure 10.



**Figure 10:** Natal cleft after 11 laser treatments

#### **Pain Control - Cooling**

Skin cooling is the optimal modality to reduce pain and provide epidermal protection during laser/IPL treatment. Options include pre-, inter- and post-treatment cooling using:

- Refrigerated clear ultrasound transmission gel. Ultrasound gel serves to both cool the skin and couple the laser/IPL light into the skin and can assist to show where the applicator tip has been applied.
- Direct/parallel contact cooling i.e. thermoelectric cooling technology for pre-cooling the skin before and during the laser/IPL pulse through a crystal waveguide, metal contact pad or probe.
- Forced-air convection cooling.
- Cooling gel packs or ice from the refrigerator. (Do not use ice directly onto the skin - wrap in clean towelling or equivalent before applying over the treatment area). Cooling periods should be extended for all delicate areas.
- Oral pain relief such as paracetamol may be taken about an hour before treatment.

Care should be taken to use ice from the refrigerator and NOT the freezer as very cold ice cubes or cooling gel packs may cause frostbite. The water from melting ice or gel fills the microscopic crevices and topographic imperfections on the skin surface and helps eliminate trapped air, which has poor thermal conductivity. It also assists the transfer of heat from skin to the laser applicator crystal window, light-guide or cooling gel layer.

The importance of careful skin cooling cannot be overstated. Insufficient cooling can result in epidermal injury (burns, hyper and/or hypopigmentation) while too much cooling can produce an ineffective treatment or epidermal injury with subsequent pigmentation abnormality. Caution and adherence to manufacturer's instructions is essential when using a laser device that employs cryogen spray [29].

#### **Client Aftercare**

- Immediately after treatment, the area can be cooled to improve client comfort and reduce redness (using a cold compress and possibly soothing aloe vera gel or similar).
- To minimise the risk of post inflammatory hyperpigmentation, the client should use sun-block and avoid any sun or tanning bed exposure on the treated area for 4 weeks following treatment.
- Avoid perfumed products, hot baths, saunas etc. for 24 to 48 hours
- Avoid wearing tight clothing and strenuous exercise for 24-48 hours

#### **Delegation of Photoepilation**

When laser hair reduction is performed by trained staff or independent laser therapists under physician oversight, maximum use of time and resources can be achieved, while maintaining a high standard of safety.

#### **Adverse Effects & Safety Precautions**

Powerful Class 4 lasers and intense pulsed light (IPL) systems are a serious eye hazard for risk of injury to the pigmented iris and retina of both the operator and client. Suitable protective eye wear must be worn by every person in the treatment room.

The treatment of pigmented naevi should be avoided, or these lesions should be covered with white adhesive tape before treating skin in the area because incidental treatment of melanocytic nevi during laser hair removal has been reported to cause clinical and dermoscopic changes that may appear similar to findings seen in atypical or neoplastic melanocytic lesions [30].

Inappropriate high energy delivery, poor client skin type selection or failure to recognise variations in skin colour in intimate body areas may result in hyper or hypopigmentation. Hyperpigmentation is a particular risk following subsequent post treatment exposure to strong ultraviolet light e.g. sun bathing or tanning bed exposure.

In general, darker skin should be treated with longer pulse durations, lower energy density and additional post-treatment cooling. Low energy photoepilation treatments have been shown to permanently reduce unwanted hair following multiple treatments [30-35]. Darker skinned clients should be advised that safe and effective treatment will likely involve more treatment sessions than for lighter skinned clients.

#### **Disclaimer**

These guidelines for photoepilation on intimate body areas are based on the clinical and professional experience of the authors and their colleagues in photoepilation practice and on articles in peer reviewed literature referenced in this publication. Following these guidelines will not guarantee a safe and successful treatment outcome in all cases. Ultimate responsibility for the assessment and delivery of a specific procedure must be made by the laser/IPL operator delivering the treatment after considering the individual circumstances presented by the client.

#### **Acknowledgment**

The authors kindly acknowledge the assistance of Dr Daniel Fleming FACCSM (Surg), Former President, Australian College of Cosmetic Surgery and Medicine, Australia for reviewing this manuscript.

## References

1. Prabhune AG, Nagrath D, Vimal P. Systematic review of prevalence, attitude, and practices of pubic hair removal activities. *Journal of Behavioral Health*. 2019. 8: 170-176.
2. Herbenick D, Schick V, Reece M, Sanders S, Fortenberry DJ. Pubic hair removal among women in the United States: Prevalence, methods, and characteristics. *Journal of Sexual Medicine*. 2010. 7: 3322-3330.
3. Herbenick D, Hensel D, Smith NK, Schick V, Reece M, Sanders SA, Fortenberry JD. Pubic hair removal and sexual behavior: Findings from a prospective daily diary study of sexually active women in the United States. *Journal of Sexual Medicine*. 10: 678-685.
4. Drosner M, Adatto M. Photo-Epilation: Guidelines for care from the European Society for Laser Dermatology (ESLD) *J Cosmet Dermatol*. 2005. 7: 32-38.
5. Bjerring P, Egekvist H, Blake T. Comparison of the efficacy and safety of three different depilatory methods. *Skin Research and Technology*. 1998. 4: 196-198.
6. Town G, Botchkareva N, Uzunbajakava N, Nuijs A, van Vlimmeren M, Ash C, Dierickx C. Light-based home-use devices for hair removal: Why do they work and how effective they are? *Lasers Surg Med*. 2019. 51: 481-490.
7. Trelles M, Ash C, Town G. Clinical and Microscopic Evaluation of Long-Term Epilation Effects of the iPulse Personal Home-Use Intense Pulsed Light (IPL) Device. *J Eur Acad Dermatol Venereol*. 2014. 28: 160-168.
8. Lloyd JR, Mirkov M. Long-term evaluation of the long-pulsed alexandrite laser for the removal of bikini hair at shortened treatment intervals. *Dermatol Surg*. 2000. 26: 633-637.
9. Daggett C, Daggett A, McBurney E, Murina A. Laser safety: the need for protocols. *Cutis*. 2020. 106: 87-92.
10. Prudente de Oliveira Sangiorgi ML, Alves da Silva Lara L, Lerri MR, Ferriani RA, Romão APMS. The Preference of Women and Men Regarding Female Genital Depilation. *Rev Bras Ginecol Obstet*. 2017. 39: 488-495.
11. Bono M. *Real World Electrology: The Blend Method: The Illustrated Manual of Electrolysis*. A.R.Hinkel Co. 1984.
12. Carter, E, Saade D, Vashi N. Presurgical Laser Hair Removal: Protocoling a Safe and Effective Procedure for Transgender Patients, *Transl Androl Urol*. 2016. 5: 381-387.
13. Zhang WR, Garrett GL, Arron ST, Garcia MM. Laser hair removal for genital gender affirming surgery. *Transl Androl Urol*. 2016. 5: 381-387.
14. Currie AR, Gibson T, Goodall AL. Interdigital sinuses of barbers' hands. *Br J Surg*. 1953. 41: 178-286.
15. Goudarzi HA, McColl I. Pilonidal sinus of the prepuce. *Br Med J*. 1976. 2: 150.
16. McLeod RG. Pilonidal sinus of the suprapubic region. *Br Med J*. 1953. 1: 710.
17. Liyanage ASD, Woods Y, Javed MA, Deftly C, Shaban H, et al. Laser depilation as adjuvant therapy in prevention of recurrence of pilonidal sinus disease: initial experience of a district general hospital in the UK. *Ann R Coll Surg Engl*. 2020. 102: 685-688.
18. Lavelle M, Jafri Z, Town GA. Recurrent pilonidal sinus treated with epilation using a ruby laser. *J Cutan Laser Ther*. 2002. 4: 45-47.
19. Odili J, Gault D. Laser depilation of the natal cleft--an aid to healing the pilonidal sinus. *Ann R Coll Surg Engl*. 2002. 84: 29-32.
20. Landa N, Aller O, Landa-Gundin N, Torrontegui J, Azpiazu JL. Successful Treatment of Recurrent Pilonidal Sinus. *Dermatol Surg*. 2005. 31: 726-728.
21. Schulze SM, Patel N, Hertzog D, Fares LG. Treatment of pilonidal disease with laser epilation *Am Surg*. 2006. 72: 534-537.
22. Benedetto AV, Lewis AT. Pilonidal sinus disease treated by depilation using an 800 nm diode laser and review of the literature. *Dermatol Surg*. 2005. 31: 587-591.
23. Oram Y, Kahraman F, Karıncaoglu Y, Koyuncu. Evaluation of 60 patients with pilonidal sinus treated with laser epilation after surgery *Dermatol Surg*. 2010. 36: 88-91.
24. Jain V, Jain A. Use of lasers for the management of refractory cases of hidradenitis suppurativa and pilonidal sinus. *J Cutan Aesthet Surg*. 2012. 5: 190-192.
25. Halleran DR, Onwuka AJ, Lawrence AE, Fischer BC, Deans KJ, et al. Laser Hair Depilation in the Treatment of Pilonidal Disease: A Systematic Review. *Surg Infect (Larchmt)*. 2018. 19: 566-572.
26. Shafiq Y, Beheshti A, Charkhchian M, Rad FS. Successful treatment of pilonidal disease by intense pulsed light device. *Adv Clin Exp Med*. 2014. 23: 277-282.
27. Kelly KM, Svaasand LO, Stuart Nelson J. Optimization of Laser Treatment Safety in Conjunction with Cryogen Spray Cooling. *Arch Dermatol*. 2003. 139: 1372-1373.
28. Courtesy Lavelle M, Jafri Z, Town GA. Recurrent pilonidal sinus treated with epilation using a ruby laser. *J Cutaneous Laser Therapy*. 2002. 4: 45-47.
29. Cices A, Dover JS, Labadie JG. Changes in melanocytic nevi treated with laser hair removal: A systematic review *Lasers Surg Med*. 2023. 55: 617-624.
30. Krauss MC. Removal of Bikini Hair Using a Rapid 810-nm Diode Laser. *Cosmet Derm*. 2008. 7: 392-396.
31. Royo J, Urdiales F, Moreno J, Al-Zarouni M, Cornejo P, et al. Six-month follow-up multicenter prospective study of 368 patients, phototypes III to V, on epilation efficacy using an 810-nm diode laser at low fluence. *Lasers Med Sci*. 2011. 26: 247-255.
32. Braun M. Comparison of High-fluence, Single-pass Diode Laser to Low-fluence, Multiple-pass Diode Laser for Laser Hair Reduction With 18 Months of Follow Up. *J Drugs Derm*. 2011. 10: 62-65.
33. Drosner M, Stangl S, Hertenberger B, Klimek H, Pettke-Rank C. Low dose epilation by alexandrite laser: A dose response study. *Med Laser Appl*. 2001. 16: 293-298.
34. Trelles M, Ash C, Town G. Clinical and Microscopic Evaluation of Long-Term Epilation Effects of the iPulse Personal Home-Use Intense Pulsed Light (IPL) Device. *J Eur Acad Dermatol Venereol*. 2014. 28: 160-168.
35. Town G, Botchkareva N, Uzunbajakava N, Nuijs A, van Vlimmeren M, et al. Light-based home-use devices for hair removal: Why do they work and how effective they are? *Lasers Surg Med*. 2019. 51: 481-490.