ISSN: 2977-0033

Case Report

Journal of Clinical Research and Case Studies

Cystadenoma of the Tongue: A Case Report

Niema Benkhraba[1,3*], Kawtar Ayyad[1,3], Razika Bencheikh[2,3], Mohamed Anas Benbouzid[2,3], Abdelilah Oujilal[2,3] and Leila Essakalli Houssyn[2,3]

[1]*Resident physician in otolaryngology, Department of Otolaryngology, Head and Neck Surgery, Ibn Sina University Hospital, Rabat, Morocco*

[2]*Professor of otolaryngology, Department of Otolaryngology, Head and Neck Surgery, Ibn Sina University Hospital, Rabat, Morocco*

[3]*Faculty of Medicine and Pharmacy of Rabat, Mohamed V University, Rabat, Morocco*

[*]Corresponding author
Niema Benkhraba, Resident physician in otolaryngology, Department of Otolaryngology, Head and Neck Surgery, Ibn Sina University Hospital, Rabat, Morocco.

Received: August 12, 2024; **Accepted:** August 19, 2024; **Published:** August 23, 2024

ABSTRACT
Cystadenoma is a rare benign salivary gland neoplasm characterized by a predominantly multicystic growth pattern. The parotid gland is involved in about 45-50% of cystadenoma cases, with the minor glands of the lip and buccal mucosa being the next most common sites. The tongue is rarely involved. We report the case of a 56-year-old patient who presented a cystadenoma of the base of the tongue.

Keywords: Cystadenoma, Benign Salivary Gland Neoplasm, Tongue

Introduction

Cystadenoma is a rare benign salivary gland neoplasm characterized by a predominantly multicystic growth pattern. It accounts for 4% of all salivary gland neoplasms [1]. Cystadenoma was classified as a separate type of salivary gland neoplasm in 1991 by the World Health Organization (WHO) and further refined into its two major variants of papillary and mucinous cystadenomas in 2005 [2,3]. Most cystadenomas of the oral cavity are of the papillary type; mucinous cystadenoma is rare. Due to the abolition of these variants, the rare appearance of mucous cells in cystadenoma was documented in the 2017 WHO classification [1]. The parotid gland is involved in about 45–50% of cystadenoma cases, with the minor glands of the lip and buccal mucosa being the next most common sites [1]. The tongue is rarely involved; only one congenital case was reported in the literature [4].

Case Report

This is a 56-year-old patient who has had swelling and pain of the tongue for 3 months. The clinical examination reveals a swelling of the left posterolateral part of the base of the tongue, measuring approximately 3 cm, of firm consistency, not painful, without associated cervical lymphadenopathy. The CT scan showed a tissue process of spontaneously high density, slightly enhanced after injection of contrast product, developed at the level of the left posterolateral part of the base of the tongue. The process measures approximately 3*2.7*4.5cm (AP*W*H). The lesion comes into contact with the left mandibular cortex without any sign of its invasion. The lesion protrudes into the oropharynx and makes close contact with the left mylohyoid muscle. A biopsy was performed, the histological study of which came back in favor of a cystadenoma. A complete excision of the mass was done. The postoperative course was uneventful, and we found no evidence of recurrence at the postoperative 4-years follow-up.

Citation: Niema Benkhraba, Kawtar Ayyad, Razika Bencheikh, Mohamed Anas Benbouzid, Abdelilah Oujilal, et al. Cystadenoma of the Tongue: A Case Report. J Clin Res Case Stud. 2024. 2(3): 1-3. DOI: doi.org/10.61440/JCRCS.2024.v2.45

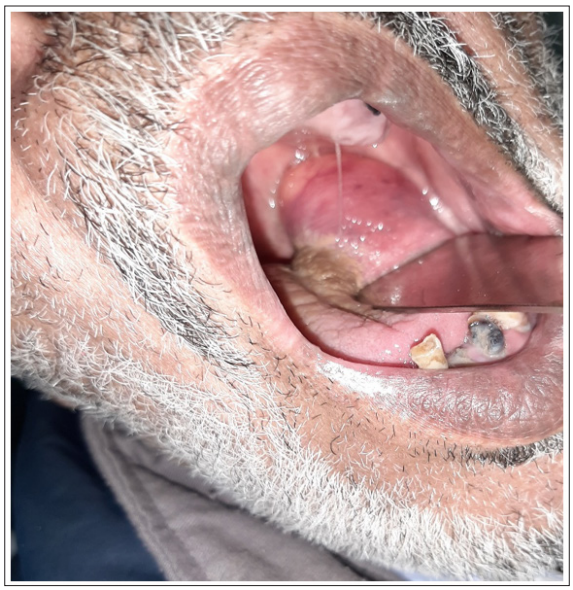

Figure 1: Clinical appearance of the lesion

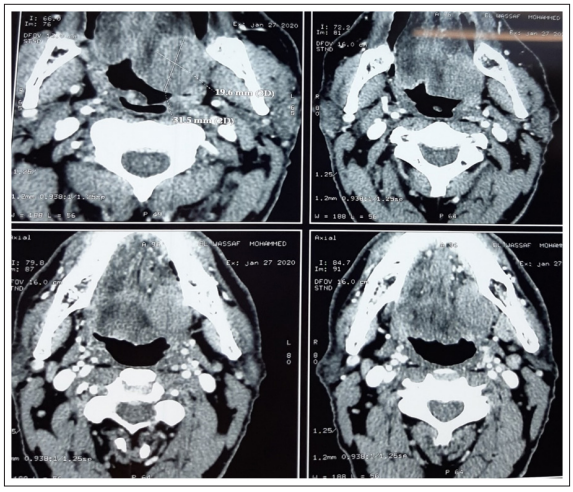

Figure 2: CT scan showing voluminous tissue process of the left posterolateral part of the base of the tongue protruding into the oropharynx and establishing close contact with the mylohyoid muscle

Discussion

The initial abnormal sign in the present case was slight swelling and pain in the tongue. Pain is an important symptom in oral tumours. In palatal salivary gland tumours, pain and colour alteration were reported to be independent predictors of malignancy [5]. However, the relationship between tumour progression and pain is not obvious.

Image evaluation by CT scan, magnetic resonance imaging or echography is usually preferable before resection.

Histopathological differential diagnosis includes ductal ectasia, Warthin tumour, and low-grade mucoepidermoid carcinoma. Ductal ectasia occurs secondarily to salivary obstruction and is characterized by oncocytic metaplasia of the epithelium however, we observed no obstructive features, such as fibrosis and/or hyalinization of stroma with inflammatory cell infiltration, and clear cells were scattered in the lining epithelium [6]. Warthin tumour has a pronounced lymphoid stroma and bilayered oncocytic epithelium, whereas in cystadenoma, the epithelium is usually not bilayered and lacks lymphoid stroma (however, one case of cystadenoma with unusual prominent lymphoid stroma has been reported) [7,8]. Cystic cavities in the present case were lined by a bilayered epithelium composed of luminal columnar cells and basal cuboidal cells. The stroma was fibrous connective tissue without lymphocytic components. The lack of lymphocytic components thus excluded Warthin tumour. The low-grade mucoepidermoid carcinoma is prominently cystic. Its salient features are infiltrative borders and noncystic epithelial proliferation [7].

Recommended treatment for cystadenoma is complete surgical removal. Recurrence is rare. However, mucinous cystadenoma with malignant transformation and cystadenoma with cervical metastasis have both been reported [9,10]. Therefore, although 4 years have passed after surgery in the present case, long-term clinical follow-up is scheduled.

Conclusion

Cystadenoma is a rare benign salivary gland neoplasm. The diagnostic is histologic. the recommended treatment is simple surgical excision, although follow-up of the patient is necessary since recurrences due to incomplete excision have been reported.

References

1. Budnic S, Simpson RHW. Cystadenoma In: El-Naggar AK, JKC C, Grandis JR, Takata T, Slootweg PJ (eds). WHO Classification of Head and Neck Tumours, 4th edn. Lyon: International Agency for Research on Cancer. 2017. 191-192.
2. Seifert G, Sobin LH. World Health Organization International Classification of Tumors: Histological Typing of Salivary Gland Tumors, 2nd edn. Berlin: Spring-Verlag. 1991. 16-17.
3. Skalova A, Michal M. Cystadenoma In: Barnes L, Eveson JW, Reichart P, Sidransky D (eds). WHO Classification of Tumours. Pathology and Genetics of Head and Neck Tumours. Lyon: International Agency for Research on Cancer. 2005. 273-274.
4. Kacker A, de Serres LM. Congenital cystadenoma of the tongue in a neonate case report with review of literature. Int J Pediatr Otorhinolaryngol. 2001. 60: 83.
5. Mariz BALA, do Socorro Queiroz Feio P, Roza ALOC, de Andrade BAB, Agostini M, et al. Clinical predictors of malignancy in palatal salivary gland tumors. Oral Dis. 2019. 25: 1919-1924.
6. Neville BW, Damm DD, Allen CM, Chi AC. Oral and Maxillofacial Pathology, 4th edn. St. Louis: Elsevier. 2016. 422-427.
7. Ellis GL, Auclair P. Tumors of the Salivary Glands. AFIP Atlas of Tumor Pathology Series 4. Washington DC: Armed Forces Institute of Pathology. 2008. 117-123
8. Pahl S, Püschel W, Federspil P. Cystadenoma of the parotid gland with unusual prominent lymphoid stroma. J Laryngol Otol. 1997. 111: 883-885.

9. Michal M, Skálová A, Mukensnabl P. Micropapillary carcinoma of the parotid gland arising in mucinous cystadenoma. Virchows Arch. 2000. 437: 465-468.
10. Wu WJ, Huang MW, Gao Y, Zhang JG. Cystadenoma of minor salivary gland with cervical metastasis: benign or malignant? J Oral Maxillofac Surg. 2018. 76: 670-675.

Copyright: © 2024 Niema Benkhraba, et al. This is an open-access article distributed under the terms of the Creative Commons Attribution License, which permits unrestricted use, distribution, and reproduction in any medium, provided the original author and source are credited.