

## Conservative Management of Chronic Subdural Haematomas

Abdulrahim Zwayed<sup>1\*</sup>, Sreenivas AV<sup>1</sup>, Balola Miraghani<sup>1</sup>, Enas Hasan<sup>1</sup>, Amal Al Hashimi<sup>2</sup>, Mohammed Ali ALZoubi<sup>3</sup> Vinita<sup>3</sup>, Amir M. Shabana<sup>4</sup>, Faisal Khalfan Al Balushi<sup>4</sup>, Wajih K. Eshak<sup>4</sup>, Yasser Abdul Raziek<sup>5</sup>, Halima Mohammed Al Amri<sup>5</sup>, Ahmed Sulaiman<sup>5</sup>, Alaa Yasin Hasan<sup>6</sup> and Abdulrahman Abdullah Al Yamani<sup>6</sup>

<sup>1</sup>Department of Neurosurgery, Sohar Hospital, Sultanate of Oman

<sup>2</sup>Department of Neurologist: Khoula Hospital, Sultanate of Oman

<sup>3</sup>Department of Neurologist: Sohar Hospital, Sultanate of Oman

<sup>4</sup>Department of Anaesthesia: Sohar Hospital, Sultanate of Oman

<sup>5</sup>Department of Radiology: Sohar Hospital, Sultanate of Oman

<sup>6</sup>Department of Intensive care unit: Sohar Hospital, Sultanate of Oman

### \*Corresponding author

Abdulrahim-Rahim H Zwayed, Department of Neurosurgery, Sohar Hospital, Sultanate of Oman.

Received: April 3, 2024; Accepted: May 02, 2024; Published: May 06, 2024

### ABSTRACT

Between Jan./2016 and Dec./2023(=8 years) chronic subdural haematoma cases were diagnosed in 82 patients at the Department of Neurosurgery. In this report we evaluate the therapeutic results retrospectively. The treatment was surgical in 44 patients, while 38 patients were treated medically, i.e., with corticosteroids, symptomatic medication and physiotherapy. Four surgical patients developed a recurrence which was then also treated medically. Of the 38 patients in the medically treated group, 3 had to undergo surgery later. Operose patients with distinct focal symptoms and comatose patients with incipient herniation received immediate surgical treatment. Of the 38 medically treated patients, (31 =81% were symptoms-free and 7= 19% showed residual symptoms).

**Keywords:** Chronic, Subdural Haematoma, Rankin Scale, Conservative, Dexamethasone

- Hypo dense or isodense subdural collection on CT-scan.
- Patients with grade 1- 4 on modified Rankin Scale (mRS) at admission

### Materials and Method

This prospective case study was done for 96 months from Jan.2016 to Dec.2023. On admission, the parenteral steroid dexamethasone (4 mg) was given every 8 hours for 5 days then 4 mg every 12 hours for 5 days then 4 mg once daily for 5 days then if the patient improved, the oral tapering doses of steroids were continued for 1 month. Neurological assessment and computed tomography scan done after 4-6 weeks.

If the patient had not improved at the first 5 days, a standard burr hole and evacuation was done. We performed a retrospective analysis using data collected from medical records of all patients admitted in the ward under neurological and neurosurgical teams care with the diagnostic of chronic subdural hematoma during the period from (Jan.2016 to Dec.2023.)

The inclusion criteria were:

- Patients of both genders (25 M. And 13 F.)
- Age > 50 (between 54 years and 87 years old)

**Table 1: Rankin Scale (mRS)**

score	Functional state
0	No symptoms
1	No significant disability, able to carry out all usual activities despite some symptoms
2	Slight disability. Able to look after personal affairs without assistance but unable to carry out all previous activities
3	Moderate disability. Requires some help, but able to walk unassisted
4	Moderate severe disability. Unable to attend to own body needs without assistance and unable to walk unassisted
5	Severe disability. Requires constant nursing care and attention, bedridden, incontinent
6	dead

**Citation:** Abdulrahim Zwayed, Sreenivas AV, Balola Miraghani, Enas Hasan, Amal Al Hashimi, et al. Conservative Management of Chronic Subdural Haematomas. J Clin Psychol Neurol. 2024. 2(2): 1-5. DOI: doi.org/10.61440/JCPN.2024.v2.19

**Table 2: The cases of non-surgical management of CSDH**

ID	AGE	SEX	SIZE	MIDLINE SHIFT	SITE	Rankin scale
1	59 y	F	17 mm	3mm	Left parietal	2
2	65 y	F	26 mm	7 mm	Right fronto tempero parietal	4
3	75 y	M	14 mm	3 mm	Right tempero parietal	3
4	54y	F	25 mm	6 mm	Left fronto tempero parietal	4
5	87 y	M	28 mm	5 mm	Right parietal	2
6	75 y	M	22/19mm	3mm	Bifronto parietal (bilateral)	3
7	63 y	F	11mm	4 mm	Right fronto tempero parietal	3
8	58 y	M	12 mm	3 mm	Left fronto tempero parietal	3
9	59y	M	15 mm	4 mm	Left fronto tempero parietal	3
10	71 y	M	17 mm	5mm	Right fronto- tempero parietal	2
11	64y	M	13 mm	3mm	Right fronto tempero parietal	2
12	67y	F	23 mm	7mm	Left fronto tempero parietal	4
13	55y	M	18 mm	4mm	Left parietal	3
14	62y	M	24 mm	8mm	Right fronto tempero parietal	4
15	58y	M	17 mm	5 mm	Left tempero parietal	3
16	557	F	27 mm	7 mm	Right tempero parietal	4
17	63y	M	25mm	6 mm	Right parietal	4
18	59y	F	22 mm	5 mm	left fronto parietal (bilateral)	4
19	57y	F	15mm	4 mm	Right fronto tempero parietal	3
20	65y	M	12 mm	3 mm	Right tempero parietal	2
21	72y	M	16 mm	4 mm	Left fronto tempero parietal	2
22	69y	M	19 mm	4mm	Right fronto- tempero parietal	3
23	61 y	F	13 mm	5mm	Left parietal	3
24	64 y	M	17 mm	5mm	Right fronto tempero parietal	4
25	81 y	M	26 mm	6 mm	Right tempero parietal	4
26	56y	F	15 mm	4 mm	Left fronto tempero parietal	3
27	80 y	M	24 mm	7 mm	Right parietal	4
28	71 y	F	27 mm	7 mm	Right fronto parietal (bilateral)	4
29	81 y	M	23 mm	6 mm	Right fronto tempero parietal	4
30	58 y	M	15mm	3mm	Left fronto tempero parietal	3
31	54y	F	16 mm	4 mm	Left tempero parietal	3
32	71 y	F	15 mm	5 mm	Right fronto- tempero parietal	2
33	65y	M	18 mm	4 mm	Left parietal	3
34	57y	M	16 mm	4 mm	Right parietal	2
35	61y	M	22mm	6 mm	Right fronto- tempero parietal	3
36	67 y	M	20 mm	5 mm	Left fronto- tempero parietal	3
37	58y	M	16 mm	3 mm	Right tempero parietal	2
38	69y	M	20 mm	4 mm	Left tempero parietal	4

**Treatment protocol**

Dexamethasone was administered following the same protocol in all patients:

1\*12 mg per day, every day during the first 5 days then

2\* 8 mg daily in the second 5 days and

3\*Then 4 mg once every day in the third 5 days

4\*Then to continue oral medication for 3- 4 weeks with follow up Brain CT after complete the course of dexamethasone (or in case of any deterioration) and deals accordingly

**Table 3: (Medication in the hospital as I.V. route)**

Dose	Day
4 mg T.I.D	5
4 mg B.I.D	5
4 mg O.D	5

Radiology

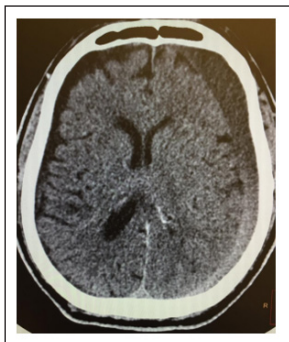


Figure: 1

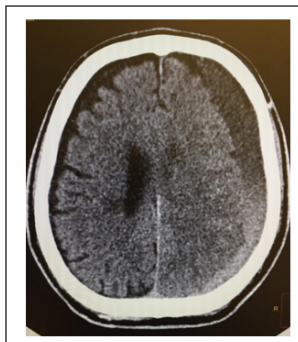


Figure: 2

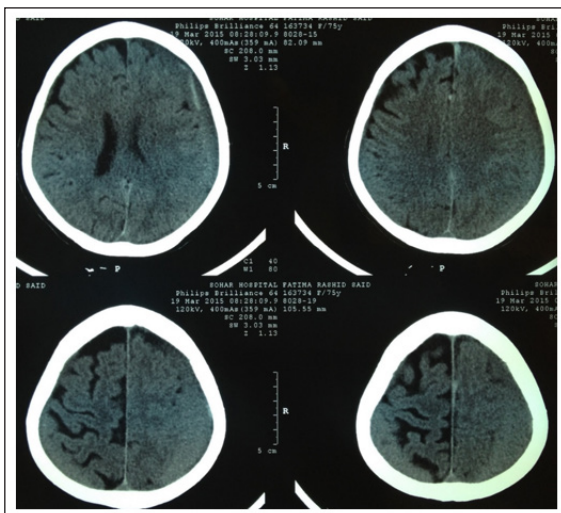


Figure: 3

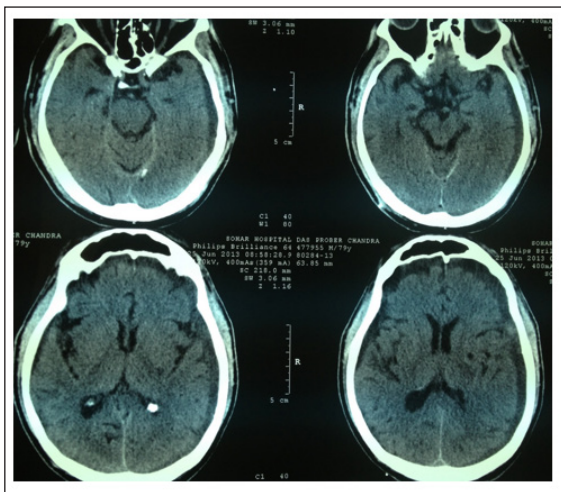


Figure: 4

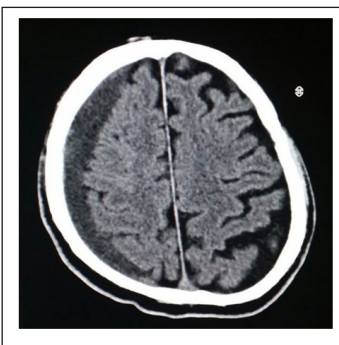


Figure: 5

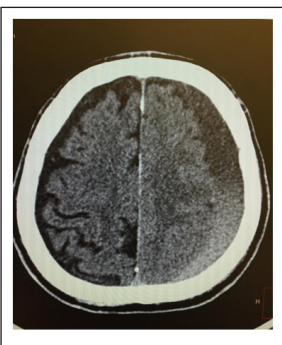


Figure: 6

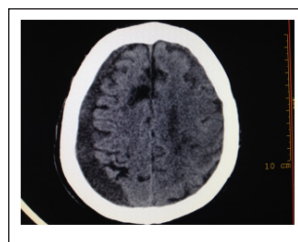


Figure: 7

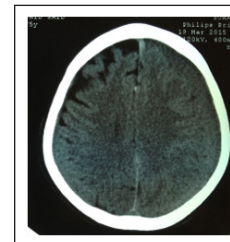


Figure: 8

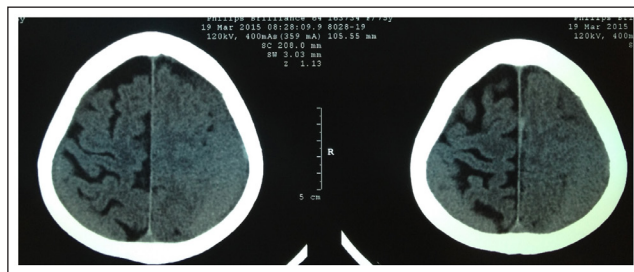


Figure: 9

Bilateral CSDH

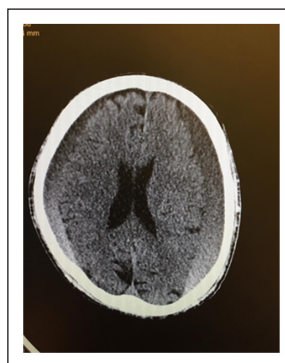


Figure: 10

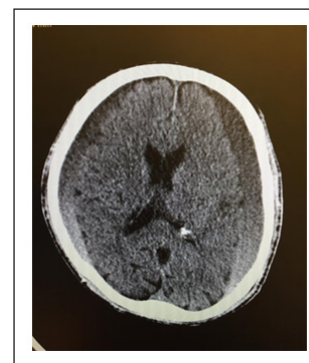


Figure: 11

Resolving status

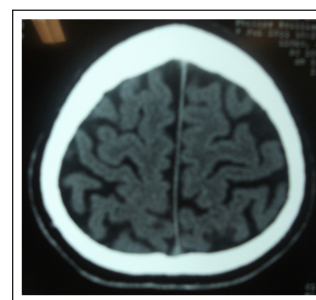


Figure: 12

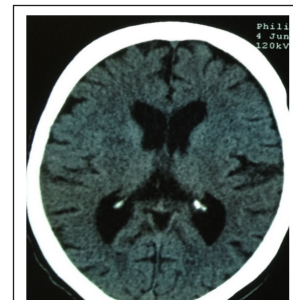


Figure: 13

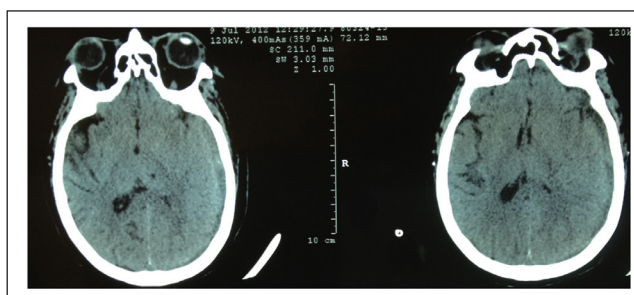
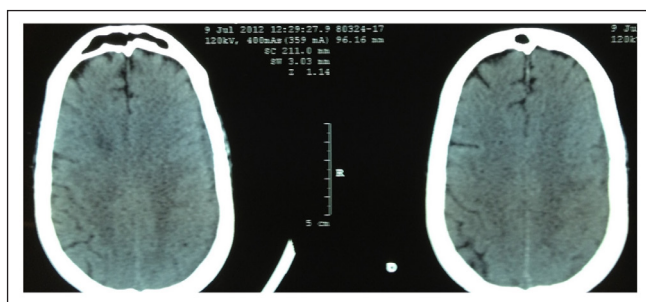


Figure: 14





**Figure: 15**

## Results

Thirty eight out of Eighty-two patients were treated conservatively and were studied (25 men; 13 females, mean age, 64.8 years). The average thickness of the hematoma was 18 mm, the mean midline shift was 4.7 mm, and the average attenuation value of bleed on computed tomography scan was 33.5. Thirty-eight were treated successfully with steroid treatment, whereas 44 patients required surgery. The female gender, less midline shift, less density (Hounsfield units) was noted to be associated with successful medical treatment. We propose a grading based on the total score given to the midline shift and density.

Four surgical patients developed a recurrence which was then also treated medically. Of the 38 patients in the medically treated group, 3 had to undergo surgery later. Operose patients with distinct focal symptoms and comatose patients with incipient herniation received immediate surgical treatment. Of the 38 medically treated patients, (31 =81% were symptoms-free and 7= 19% showed residual symptoms). There was no mortality

## Conclusion

Chronic subdural haematoma CSDH is a condition where blood accumulates between the arachnoid and dura mater, forming a chronic space-occupying lesion. Typically, CSDH develops about three weeks after a traumatic brain injury. Surgical treatment is often the initial choice for patients with significant space-occupying effects due to CSDH. However, considering the risks associated with surgery, especially in elderly patients with multiple comorbidities, drug treatment has gained attention as an alternative approach [1-3].

The purpose of this study was to assess whether the use of dexamethasone in patients with chronic subdural hematomas (CSDH) could lead to avoidance of surgical treatment.

Data in the literatures showed benefits of dexamethasone in selected patients, sometimes grouped in large cohorts, but studies comparing groups of patients who received or not this medication, from the point of view of surgical therapy prevention, are missing [4-6].

We analysed 84 patients with the diagnostic of chronic subdural hematoma, separated in 2 groups on the basis of presence or absence of dexamethasone therapy.

We found that 38 of patients who received dexamethasone didn't need surgical intervention, while the other (44 cases) who were not treated with dexamethasone they need surgery because of major neurological deficits.

The conservative treatment with dexamethasone can be a safe and efficient therapeutic option for CSDH, which can be used with few risks even in elderly patients with important comorbidities, [3,7- 8].

When the surgical option would be hazardous, with few exceptions, CSDH should not be considered a neurosurgical emergency, treatment with dexamethasone being usually attempted without significant risk for 48 - 72 hours [9-11].

Conservative therapy eliminates the complications related to surgery, some of which are severe [1,6].

Essentially, dexamethasone therapy involves shorter hospitalization, lower costs, rare severe complications and the possibility for outpatient treatment and follow up [2,12-13].

Comparing these results with those of surgical treatment in the literature, Dexamethasone medication can be recommended if strict guidelines are observed on other way medication should not be considered a substitute for surgery but an alternative in the majority of cases [14-16].

## In conclusion

Steroids appear to play a role in the nonsurgical medical treatment of CSDH. Patients with lower grades of CSDH can be treated successfully with steroids. Female patients seem to do better with steroids.

The neuroconservative issue in treatment some selected cases of chronic subdural haematoma depending on the clinical picture including symptoms, signs, age and comorbidities and to give chance for medication if the patient is clinically stable and to repeat Head CT after 5-7 days or in appearance of any new neurological deficit, and in medicine they said: As a rule, there is no rule.

## References

1. Almenawer SA, Farrokhyar F, Hong C, Chronic subdural hematoma management: a systematic review and meta-analysis of 348 patients. *Ann Surg.*, 2014. 259: 449-457.
2. Collaborators, Dexamethasone for adult patients with a symptomatic chronic subdural haematoma trial: study protocol for a randomized controlled trial. *Trials*, 2018. 19: 1-14.
3. Miah IP, Holl DC, Peul WC Dutch Subdural Hematoma Research Group (DSHR). Dexamethasone therapy versus surgery for chronic subdural haematoma (DECSEA trial): study protocol for a randomized controlled trial. *Trials*, 2018. 19: 1-10.
4. Berghauer-Pont LM, Dirven CM, The role of corticosteroids in the management of chronic subdural hematoma: a systematic review. *Eur J of Neurology*, 2012. 9: 1397-1403.
5. Edlmann E, Giorgi-Coll S, Whitfield PC, Pathophysiology of chronic subdural haematoma: inflammation, angiogenesis and implications for pharmacotherapy. *J Neuroinflammation*, 2017. 14: 1-13.
6. Li F, Hua C, Feng Y Correlation of vascular endothelial growth factor with magnetic resonance imaging in chronic subdural hematomas. *J Neurol Sci.*, 2017. 377: 1.

7. Apacocea, Emil Popa, Turliuc Dana, Raluca Papacocea-Department of Neurosurgery, “Sf. Pantelimon” Emergency Hospital, Bucharest, Romania FARMACIA, 2019. 67: 1.
8. Santarius T, Hutchinson PJ, Chronic subdural haematoma: time to rationalize treatment? Br J Neurosurgery, 2004. 18: 328-332.
9. Prud'homme M, Mathieu F, Marcotte N, A pilot placebo controlled randomized trial of dexamethasone for chronic subdural hematoma. Can J Neurol Sci., 2016. 43: 284-290.
10. Soleman J, Nocera F, Mariani L, The conservative and pharmacological management of chronic subdural haematoma: a systematic review. Swiss Med Wkly., 2017. 147: 1-9. 26.
11. Victoratos GC, Bligh AS, A more systematic management of subdural hematoma with the aid of CT scan. Surg. Neurol., 1981. 15: 158-160.
12. Holl DC, Volovici V, Dirven CM, Pathophysiology and non-surgical treatment of chronic subdural hematoma: from past to present to future. World Neurosurgery, 2018. 116: 402-411.
13. Sambasivan M, An overview of chronic subdural hematoma: experience with 2300 cases. Surg Neurol., 1997. 47: 418-422. 12.
14. Sun TF, Boet R, Poon WS, Non-surgical primary treatment of chronic subdural haematoma: preliminary results of using dexamethasone. Br J Neurosurgery, 2005. 19: 327-333.
15. Thotakura AK, Marabathina NR, Nonsurgical treatment of chronic subdural hematoma with steroids. World Neurosurgery, 2015. 84: 1968-1972.
16. Zhang Y, Chen S, Xiao Y, Tang W, Effects of dexamethasone in the treatment of recurrent chronic subdural hematoma. World Neurosurgery, 2017. 105: 115.