

## Combined Treatment of Peri-Implantitis in Patients with Type 2 Diabetes Mellitus

Hakob Khachatryan<sup>1</sup>, Mishel Kocharyan<sup>2</sup> and Gagik Hakobyan<sup>3\*</sup><sup>1</sup>Central clinical Military hospital (Ministry of Defence of The Republic of Armenia), Yerevan State Medical University after M. Heratsi, Yerevan, Armenia<sup>2</sup>Resident General Dentistry Yerevan State Medical University after M. Heratsi, Yerevan, Armenia<sup>3</sup>Professor, Head of Department of Oral and Maxillofacial Surgery, Yerevan State Medical University after M. Heratsi, Yerevan, Armenia**\*Corresponding author**

Gagik Hakobyan, Professor, Head of Department of Oral and Maxillofacial Surgery, Yerevan State Medical University, Yerevan, Armenia.

**Received:** March 08, 2024; **Accepted:** March 14, 2024; **Published:** March 20, 2024**ABSTRACT****Objective:** To evaluate the outcome of combined therapy of peri-implantitis in patients with type 2 diabetes mellitus.**Methods:** Study included 46 patients with type 2 diabetes mellitus diagnosed peri-implantitis. 24 implants with early peri-implantitis, 18 implants with moderate peri-implantitis. The diagnostic parameters used for assessing peri-implantitis include clinical indices, Probing Pocket Depth (PPD), Bleeding on Probing (BOP), peri-implant radiography, data at the re-examination were retrospectively compared to baseline data. Patients underwent treatment with HbA1c levels <7.2% or less than 154 mg/Dl.**Results:** A statistical significant reduction in both PPD and BOP were seen at all-time points as compared with the baseline clinical measurements. Stable clinical measurements PPD and BOP were demonstrated after 1 year the initial treatment, remaining stable during the following three years. The mean BOP in patients before treatment of peri-implantitis was  $2.5 \pm 0.31$ , after 6 months treatment month treatment  $0.6 \pm 0.1$ . The mean PPD in patients before treatment of peri-implantitis was  $5.2 \pm 0.24$ , after 6-month treatment pocket was  $3.2 \pm 0.1$ .**Conclusion:** Conservative treatment with systemic antibiotics, pocket elimination was an effective therapy in peri-implant mucositis and early periimplantitis, when peri-implantitis category moderate surgical treatment combined conservative therapy effective method in patients with type 2 diabetes mellitus.**Keywords:** Combined Treatment, Mucositis, Peri-Implantitis, Type 2 Diabetes Mellitus**Introduction**

In patients with complete and partial edentulism, rehabilitation with dental implants improves chewing function and quality of life [1-4].

Survival of implant is influenced by various local and systemic factors, among systemic factors diabetes mellitus occupies a special place [5,6].

Diabetes mellitus is a disease of the endocrine system, causing metabolic disorders, as a result of which systemic disorders of various organs and systems develop in the body [7,8].

As a result of microcirculatory disorders, wound healing slows down, the reaction to infection, macrovascular complications, impaired immunological response and bone metabolism [9].

Diabetes mellitus also negatively affects periodontal health and bone strength. Patients with diabetes often suffer from tooth loss, which requires prosthetic rehabilitation for these patients. Glycemia in patients with diabetes mellitus increases the risk of developing peri-implantitis [10-14].

A consensus report identified the prevalence (5-10 years period) of peri-implantitis to be 28% to 56% of patients and 12% to 40% of implants [15].

Inflammatory process surrounding dental implants is represented in two common forms: peri-mucositis and peri-implantitis [16]. The etiology of peri-implant diseases is characterized by various factors [17-19]. The microbiological factor plays an important role in peri-implantitis, among the detected microorganisms, *Prevotella intermedia*, *Porphyromonas gingivalis*, *Aggregatibacter actinomycetemcomitans*, *Bacterioides forsythus*, *Treponema denticola*, *Prevotella nigrescens*, *Peptostreptococcus micros*, *Fusobacterium nucleatum* [20-22]. Oral hygiene is important

**Citation:** Hakob Khachatryan, Mishel Kocharyan, Gagik Hakobyan. Combined Treatment of Peri-Implantitis in Patients with Type 2 Diabetes Mellitus. *J Stoma Dent Res.* 2024. 2(1): 1-8. DOI: doi.org/10.61440/JSDR.2024.v2.07

and the risk is high in patients who do not regularly maintain oral care after implant therapy [23]. Local factors include the volume of attached gum surrounding the implant, the volume and quality of alveolar bone tissue, the presence of periodontal diseases, and parafunctional habits [24-28].

Patient-related factors peri-implantitis include smoking, systemic diseases, osteoporosis, long-term corticosteroid treatment, chemotherapy [29-32]. Patients with type 2 diabetes are at high risk of peri-implantitis [33].

For the treatment of peri-implantitis, various treatment methods are offered, conservative methods (chemotherapeutic disinfection, use of antibacterial agents, laser therapy), surgical methods (resective and regenerative) [34-39].

But there is no standard protocol for the treatment of peri-implantitis, which necessitates the search for new therapeutic approaches [40].

A consensus report from the 2017 World Workshop on the Classification of Periodontal and Peri-Implant Diseases and Conditions emphasized the need for identifying a standard mode of therapy for the treatment of peri-implantitis [41].

Hyaluronic acid is a natural polysaccharide, which is part of the glycosaminoglycan group.

Hyaluronic acid increases local immunity in the oral cavity, by strengthening the antibacterial function of cells, stimulates the migration of fibroblasts and cell proliferation, enhances tissue regeneration, which has a positive effect on the healing process [42-44].

In the field of dentistry preliminary clinical trials have been conducted by Pagnacco and Vangelisti in 19974 [45].

Ballini et al. found that autologous bone combined with an esterified low-molecular hyaluronic acid preparation seems to have good capabilities in accelerating new bone formation in the infra- bone defects [46].

Due to its specific properties, hyaluronic acid has great potential for application in implantology practice and could be a very valuable addition to those used to treat peri- implantitis [47]. Thanks to its properties such as hygroscopicity, viscoelasticity, and antioxidant properties, HA accelerates osteogenic cell differentiation, promotes bone healing and new bone formation, soft tissue regeneration [48].

HA has a bacteriostatic effect at the wound site and may improve treatment outcomes in regenerative surgical procedures [49]. HA also has an anti-inflammatory effect, reducing inflammation, speeds up the healing process and has a bacteriostatic effect and can be used in the treatment of peri-implantitis [50,51].

## Objectives

To evaluate the outcome of regenerative therapy of peri-implantitis in patients with type 2 diabetes mellitus.

## Material and Methods

Study included 46 patients with type 2 diabetes mellitus diagnosed peri-implantitis, 24 implants with early peri-implantitis, 18 implants with moderate peri-implantitis. The diagnostic parameters used for assessing peri-implantitis include clinical indices, Probing Pocket Depth (PPD), Bleeding On Probing (BOP), Marginal Bone Loss (MBL). Peri-implant radiography, data at the re-examination were retrospectively compared to baseline data. Patients underwent treatment with HbA1c levels <7.2% or less than 154 mg/Dl.

## Treatment Protocols

Conservative therapy including systemic antibiotics (amoxicillin 500mg and metronidazole) all the above antibiotics were administered per with duration of 7-10 days. Mechanical implant cleaning with titanium or plastic-curettes, Air-Flow Perio Soft, irrigation of the circus-pocket with 0.12% chlorhexidine, magneto-laser therapy with a wavelength of 810 nm power density of 100mW during during 2min (Laser therapy apparatus MILTA-F-8-01,RF).

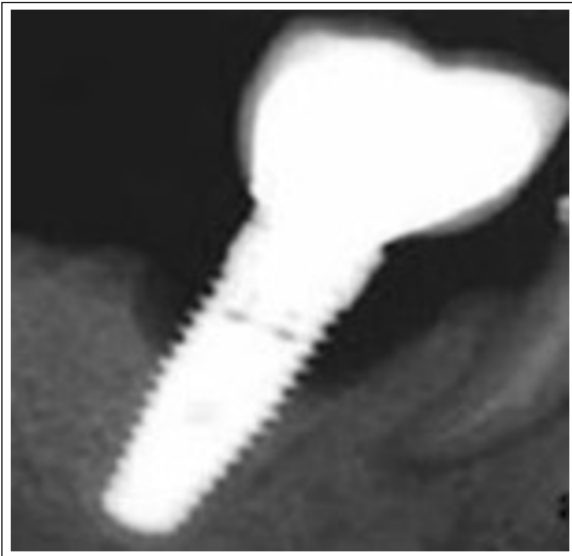
## Surgical Treatment

After local anesthesia, the superstructure was removed, incision was made around the neck of the implants and the flap of full thickness was raised to provide access to the defect of the peri-implant and the open surface of the implant. The abutment was removed and cover plugs were inserted in the implant.

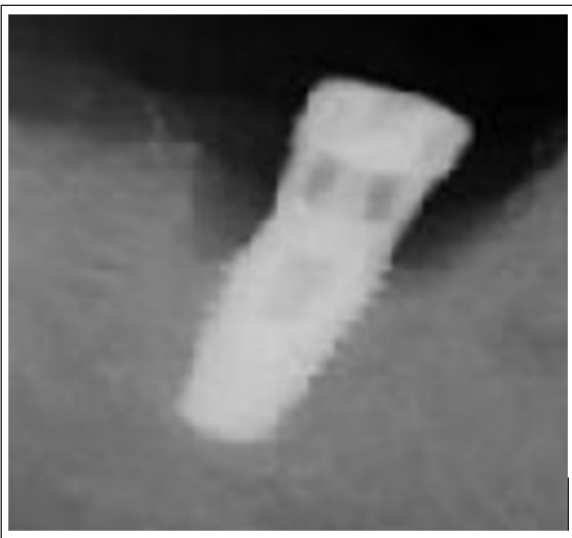
The flap of full thickness was raised to provide access to the defect of the peri-implant and the open surface of the implant. Granulation tissue was carefully removed in the bone defect with titanium instruments. The implant surface is decontaminated with successive topical applications of citric acid, 0.12% chlorhexidine, sterile physiological saline and adjunctive magneto-laser therapy with a wavelength of 810nm power density of 100mW during 30 seconds. After degranulation and antiseptic preparation, bone loss was evaluated intrasurgically. Bio-Oss had mixed with hyaluronic acid (Gengigel) and the peri-implant bone defect was filled. A membrane Bio-Gide was placed over the filled defect, flaps were repositioned and sutured, wound healing was performed in a submerged.

Patients were instructed to rinse twice a day for 1 minute for 2-3 weeks with chlorhexidine 0.12%. Healing periods occurred without complications, and with minimal postoperative discomfort. The sutures were removed 7-10 days after the surgery.

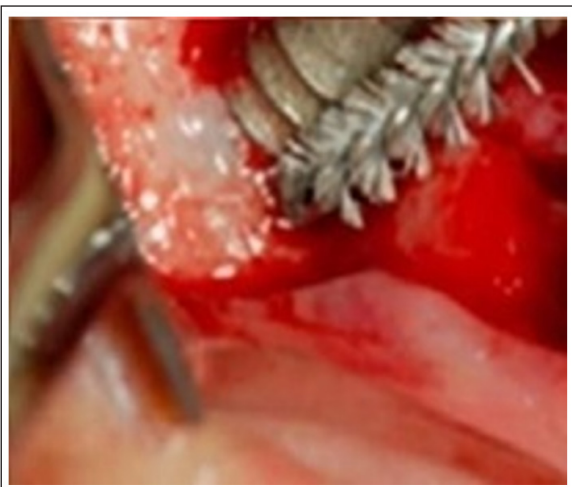After 3 months of immersed healing, the plugs from the implants were removed from the implants and replaced with gum formers, and a week later, abutments were installed and after the manufacture of new prosthetics, the structures were installed 1 week later. After treatment intraoral X-ray imaging is given (Figure 1-10). The patient was under dynamic control, and professional hygiene was carried out every six months.



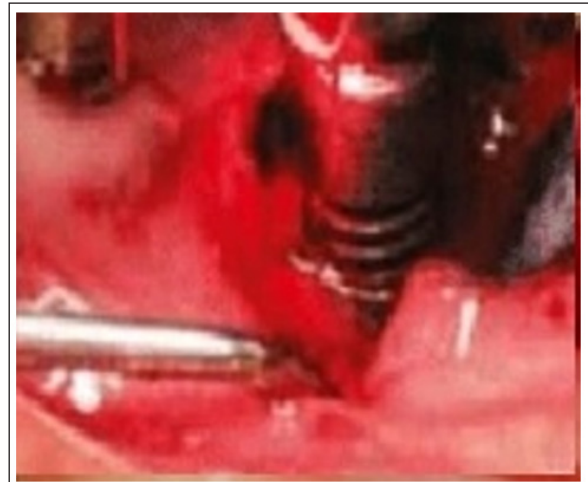**Figure 1:** X-ray of an implant with peri-implantitis before treatment



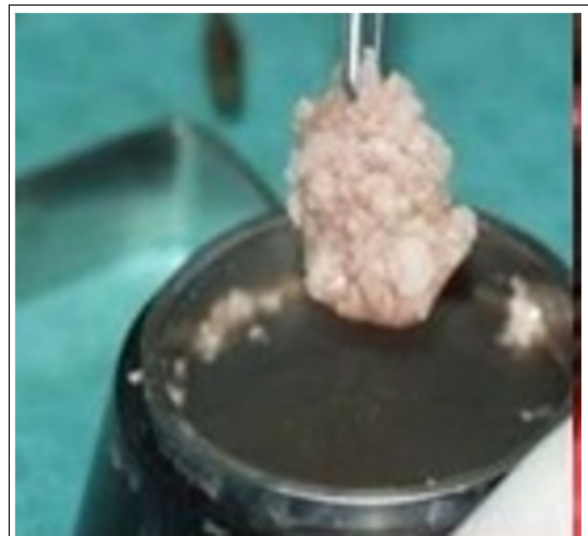**Figure 2:** X-ray of an implant with peri-implantitis before treatment implant is closed with a screw plug.



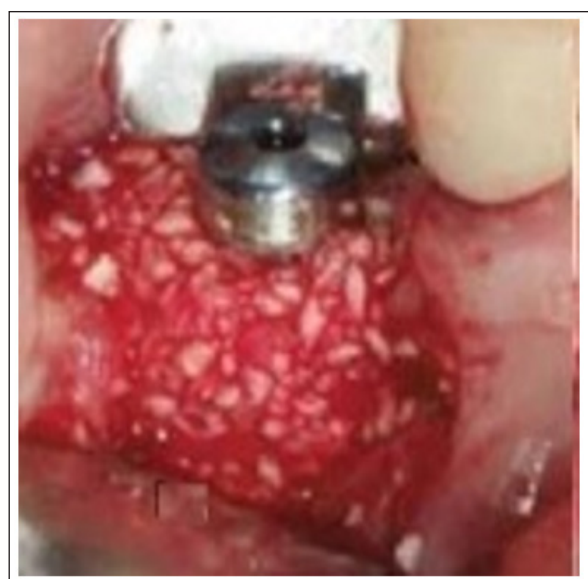**Figure 3:** With titanium instruments the implant surface is cleaned



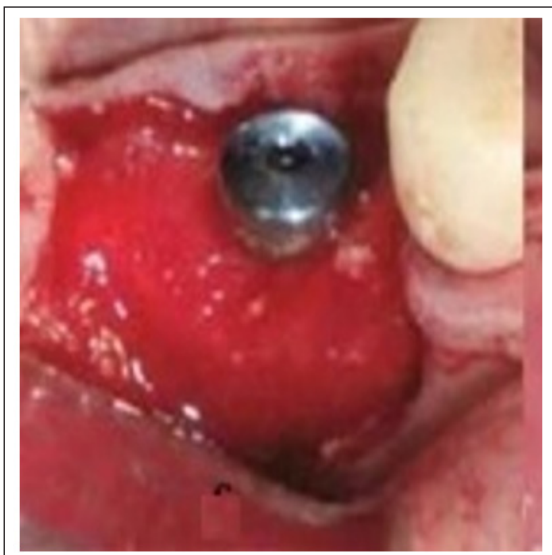**Figure 4:** Implant surface 30 seconds irradiation with magneto-laser radiation



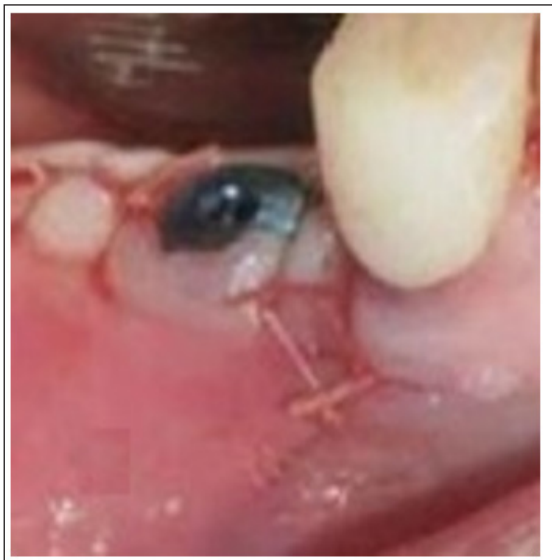**Figure 5:** The Bio-Oss was mixed with Gengigel hyaluronic acid preparation outside the mouth implant defect



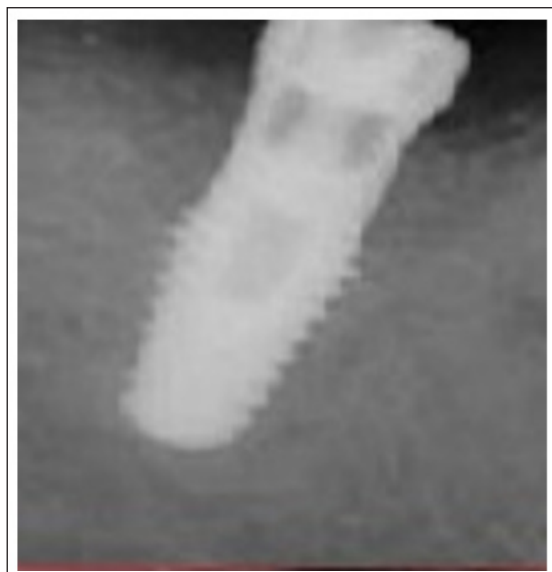
**Figure 6:** The periimplant defect was filled Bio-Oss mixed with Gengigel hyaluronic acid preparation



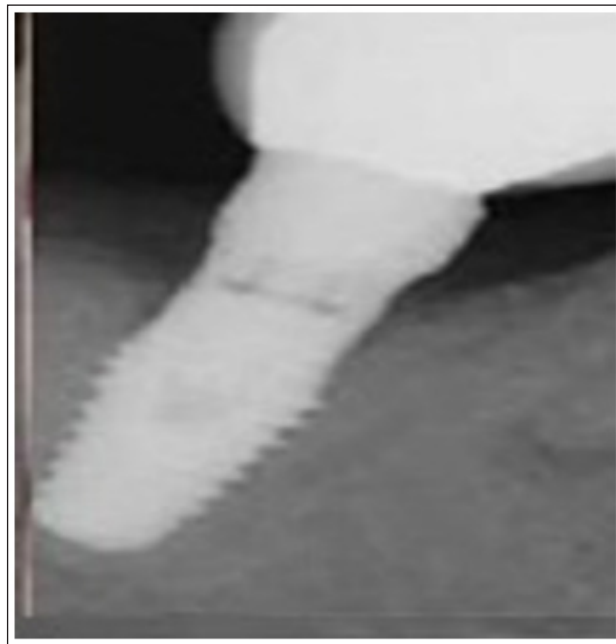**Figure 7:** A bioresorbable collagen membrane Bio-Gide was placed over the filled defect



**Figure 8:** After bone grafting flaps were repositioned and sutured.



**Figure 9:** X-ray of an implant with peri-implantitis after 4 month regenerative therapy



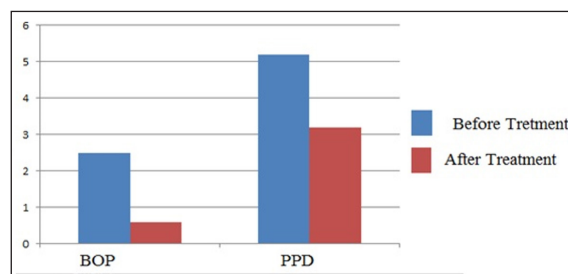
**Figure 10:** X-ray of 6 months after treatment

To assess the effectiveness of treatment, the following clinical parameters were assessed:

1. X-ray control on the marginal bone loss (MBL);
2. bleeding on probing (BOP);
3. probing pocket depth (PPD) and both groups had comparable initial results before and after treatment.

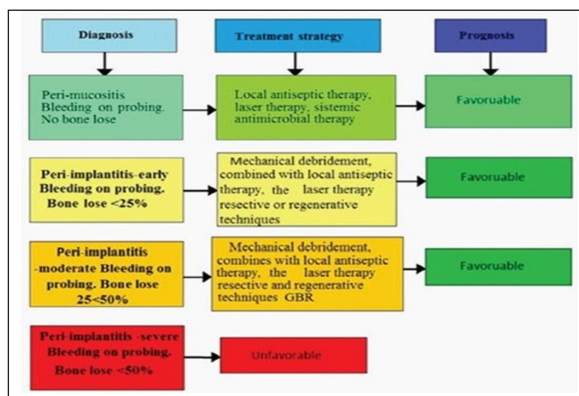
**Results**

At each follow-up visit, biological and technical complications were assessed. There was a reduction in both PPD and BOP compared to baseline clinical measurements. Stable clinical scores of PPD and BOP were demonstrated 1 year after treatment initiation and remained stable over the next three years. The average BOP value in patients before treatment for peri-implantitis was  $2.5 \pm 0.31$ , after 6 months treatment month treatment  $0.6 \pm 0.1$ . The mean PPD in patients before treatment of peri- implantitis was  $5.2 \pm 0.24$ , after 6-month treatment pocket was  $3.2 \pm 0.1$ (figure 11).



**Figure 11:** The mean BOP and PPD in patients before and after 6-month treatment treatment of peri-implantitis.

Based on the clinical experience developed Algorithm for the treatment of peri-implantitis at different stages (figure 12).



**Figure 12:** Algorithm For Treating Peri-implantitis At Different Stages

## Discussion

A review of the literature regarding the success of implantation in patients with diabetes is controversial, as hyperglycemia negatively affects wound healing and bone metabolism, which can have a significant impact on the long-term survival of dental implants [52].

In patients with diabetes mellitus, the immune response is reduced, which can increase the prevalence of postoperative infection and the development of peri-implantitis [53,54].

For successful treatment of edentulism with dental implants in patients with diabetes, plasma glucose levels must be normal or near normal (with an HbA1c level <7.2% or less than 154 mg/dl) and with periodontal disease treated [55].

A number of protocols have been suggested in the treatment of peri-implantitis includes various conservative (antibacterial pastes, emulsions) laser for therapy and surgical treatments, but none of them is universal [56-59].

Since peri-implantitis often occurs in diabetic patients with implants, the literature suggests various methods for the treatment of peri-implantation, but there is not much work devoted to the treatment of peri-implantitis in diabetics [60-63].

Thus, for the prevention and treatment of peri-implantitis in diabetic patients, it is necessary to take an integrated approach and use drugs that can have a professional inflammatory effect, enhance tissue regeneration and increase local immunity. Magnetic laser therapy exhibits immunomodulatory, anti-inflammatory, antispastic, regenerative effects and accelerating tissue healing. The magnetic field, affecting the structure of cell membranes, supports cell restoration processes, promoting the penetration of oxygen and nutrients into their insides [64-66].

It is assumed that the combined use of laser radiation and a magnetic field with a magnetic laser therapy device can increase the effectiveness of their action which requires justification based on this study in the treatment of peri-implantitis in patients with diabetes mellitus.

This study describes clinical results of a treatment of peri-implantitis in patients with type 2 diabetes mellitus.

The use of magneto-laser therapy in our study for decontamination of the affected surface of the implant has demonstrated promising results treating peri-implantitis. Magneto-laser therapy is not only beneficial because of its bactericidal effect but it can accelerate regeneration processes in peri-implant area.

The evaluation of outcomes in the present study was confined to treatment success criteria that included the combination of findings from clinical and radiological assessments. Significant reductions in both PPD and BOP were shown in the group with less pronounced bone loss pre-surgery. Based upon in our clinical experience conservative treatment methods are effective in the treatment of peri-implant mucositis and early peri-implantitis.

When peri-implantitis category moderate and severe effective surgical treatment combined conservative therapy. Implants with less bone loss before surgery presented better treatment result than more severe cases.

Hygienists play an important role in the post implant therapy as they are the first responders. They must detect any sign of inflammation around an implant [67]. But their role is first to educate the patients that the biofilm is the major risk factor for peri-implant disease.

Adequate control of periodontal infection and achievement of a stable periodontal status of the residual teeth is a key factor in increasing the long-term survival of implants, may provide a better prognosis. The long term success of peri-implant treatment requires a program of maintenance, including instructions in hygiene.

## Conclusion

Conservative treatment with systemic antibiotics, pocket elimination, was an effective therapy in peri-implant mucositis and early periimplantitis, when peri-implantitis category moderate and severe effective surgical treatment combined conservative therapy effective treatment method.

## Declarations Section

**Funding:** This research received no external funding.

**Ethics:** The study was reviewed and approved by the Ethics Committee Yerevan State Medical University after M. Heratsi (N23,29/09/2023) and in accordance with those of the World Medical Association and the Helsinki Declaration.

**Informed Consent for publication:** Patients were informed verbally and in writing about the study. Written informed consent was obtained from the patient for the publication of this case report and any accompanying images.

**Availability of Data and Materials:** All data generated or analysed during this study are included in this published article.

**Conflicts of Interest:** The authors declare no conflict of interest.

**Acknowledgements:** "Not applicable"

## References

1. Duong HY, Rocuzzo A, Stähli A, Salvi GE, Lang NP, et al. Oral health-related quality of life of patients rehabilitated with fixed and removable implant-supported dental prostheses. *Periodontol 2000*. 2022. 88: 201-237.
2. Carr AB, Revuru VS, Lohse CM. Association of systemic conditions with dental implant failures in 6,384 patients during a 31-year follow-up period. *Int J Oral Maxillofac Implants*. 2017. 32: 1153-1161.
3. Alsaadi G, Quirynen M, Michiles K, Teughels W, Komárek A, et al. Impact of local and systemic factors on the incidence of failures up to abutment connection with modified surface oral implants. *J Clin Periodontol*. 2008. 35: 51-57.
4. Nobre MA, Maló P, Gonçalves Y, Sabas A, Salvado F. Outcome of dental implants in diabetic patients with and without cardiovascular disease: a 5-year post-loading retrospective study. *Eur J Oral Implantol*. 2016. 9: 87-95.
5. Lee K, Dam C, Huh J, Park KM, Kim SY, et al. Distribution of medical status and medications in elderly patients treated with dental implant surgery covered by national healthcare insurance in Korea. *J Dent Anesth Pain Med*. 2017. 17: 113-119. View
6. Martins AS, Correia JA, Salvado F, Caldas C, Santos N, et al. Relevant factors for treatment outcome and time to healing in medication-related osteonecrosis of the jaws - a retrospective cohort study. *J Craniomaxillofac Surg*. 2017. 45: 1736-1742.
7. Atkinson MA, Eisenbarth GS, Michels AW. Type 1 diabetes. *Lancet (London, England)*. 2014. 383: 69-82.
8. From the American Diabetes Association, Alexandria, Virginia. Report of the Expert Committee on Diagnosis and Classification of Diabetes Mellitus. *Diabetes care*. 1997. 20: 1183-1197.
9. Zheng Y, Ley SH, Hu FB. Global aetiology and epidemiology of type 2 diabetes mellitus and its complications. *Nat Rev Endocrinol*. 2018. 14: 88-98.
10. Wagner J, Spille JH, Wiltfang J, Naujokat H. Systematic review on diabetes mellitus and dental implants: an update. *Int J Implant Dent*. 2022. 8: 1.
11. Khachatryan H. Dental Implant Treatment in Diabetes Mellitus (DM) Patients: Review. *Bulletin of Stomatology and Maxillofacial Surgery*. 2023. 19: 121-130.
12. Naujokat H, Kunzendorf B, Wiltfang J. Dental implants and diabetes mellitus—a systematic review. *Int J Implant Dent*. 2016. 2: 5.
13. Dubey RK, Gupta DK, Singh AK. Dental implant survival in diabetic patients; review and recommendations. *Natl J Maxillofac Surg*. 2013. 4: 142-50.
14. Naujokat H, Kunzendorf B, Wiltfang J. Dental implants and diabetes mellitus—a systematic review. *Int J Implant Dent*. 2016. 2: 5.
15. Berglundh T, Armitage G, Araujo MG, Avila-Ortiz G, Blanco J, et al. Peri-implant diseases and conditions: consensus report of workgroup 4 of the 2017 World Workshop on the Classification of Periodontal and Peri-Implant Diseases and Conditions. *J Clin Periodontol*. 2018. 45: S286-S291.
16. Schwarz F, Derks J, Monje A, Wang HL. Peri-implantitis. *J Clin Periodontol*. 2018. 45: S246-S266.
17. Renvert S, Aghazadeh A, Hallström H, Persson GR. Factors related to peri-implantitis - a retrospective study. *Clin Oral Implants Res*. 2014. 25: 522-529.
18. Dreyer H, Grischke J, Tiede C, Eberhard J, Schweitzer A, et al. Epidemiology and risk factors of peri-implantitis: A systematic review. *J Periodontol Res*. 2018. 53: 657-681.
19. Kumar PS, Dabdoub SM, Hegde R, Ranganathan N, Mariotti A. Site-level risk predictors of peri-implantitis: a retrospective analysis. *J Clin Periodontol*. 2018. 45: 597-604.
20. Ata-Ali J, Candel-Marti ME, Flichy-Fernandez AJ, Penarrocha-Oltra D, BalaguerMartinez JF, et al. Peri-implantitis: associated microbiota and treatment. *Med Oral Patol Oral Cir Bucal*. 2011. 6: 937-943.
21. de Waal YC, Eijsbouts HV, Winkel EG, van Winkelhoff AJ. Microbial Characteristics of Peri-Implantitis: A Case-Control Study. *J Periodontol* 2017. 88: 209-217.
22. Sahrman P, Gilli F, Wiedemeier DB, Attin T, Schmidlin PR, et al. The Microbiome of Peri-Implantitis: A Systematic Review and Meta-Analysis. *Microorganisms* 2020. 8: 661.
23. Durrani F, Shukla A, Painuly H. Implant therapy in patients with chronic periodontitis: A short follow-up with a successful outcome. *J Adv Periodontol Implant Dent*. 2019. 11: 39-45.
24. Pranskunas M, Poskevicius L, Juodzbalsys G, Kubilius R, Jimbo R. Influence of Peri-Implant Soft Tissue Condition and Plaque Accumulation on Peri-Implantitis: a Systematic Review. *J Oral Maxillofac Res*. 2016. 7: e2.
25. Dreyer H, Grischke J, Tiede C, Eberhard J, Schweitzer A, et al. Epidemiology and risk factors of peri-implantitis: A systematic review. *J Periodontol Res* 2018. 53: 657-681.
26. Schou S, Holmstrup P, Worthington HV, Esposito M. Outcome of implant therapy in patients with previous tooth loss due to periodontitis. *Clin Oral Implants Res* 2006.17: 104-123.
27. Lin CY, Chen Z, Pan WL, Wang HL. Is History of Periodontal Disease Still a Negative Risk Indicator for Peri-implant Health Under Supportive Post-implant Treatment Coverage? A Systematic Review and Meta-analysis. *Int J Oral Maxillofac Implants* 2020. 35: 52-62.
28. Mengel R, Behle M, Flores-de-Jacoby L. Osseointegrated implants in subjects treated for generalized aggressive periodontitis: 10-year results of a prospective, long-term cohort study. *J Periodontol* 2007. 78: 2229-2237.
29. Farronato D, Azzi L, Giboli L, Maurino V, Tartaglia GM, et al. Impact of Smoking Habit on Peri-Implant Indicators following Different Therapies: A Systematic Review. *Bioengineering (Basel)*. 2022. 9: 569.
30. Dutta SR, Passi D, Singh P, Atri M, Mohan S, et al. Risks and complications associated with dental implant failure: Critical update. *Natl J Maxillofac Surg*. 2020. 11: 14-19.
31. G Liddelow, I Klineberg. Patient-related risk factors for implant therapy. A critique of pertinent literature. *Australian Dental Journal*. 2011.
32. Moy PK, Medina D, Shetty V, Aghaloo TL. Dental implant failures and associated risk factors. *Int J Oral Maxillofac Implants* 2005. 20: 569-577.
33. Dioguardi M, Cantore S, Quarta C, Sovereto D, Zerman N, et al. Correlation between Diabetes Mellitus and Peri-implantitis: A Systematic Review. *Endocr Metab Immune Disord Drug Targets*. 2023. 23: 596-608.
34. Daugela P, Cicciù M, Saulacic N. Surgical Regenerative Treatments for Peri-Implantitis: Meta-analysis of Recent Findings in a Systematic Literature Review. *J Oral Maxillofac Res*. 2016. 7: e15.

35. Deppe H, Horch HH, Neff A. Conventional versus CO2 laser-assisted treatment of peri-implant defects with the concomitant use of pure-phase beta-tricalcium phosphate: a 5-year clinical report. *Int J Oral Maxillofac Implants*. 2007. 22: 79-86.
36. Roos-Jansåker AM, Renvert H, Lindahl C, Renvert S. Surgical treatment of peri-implantitis using a bone substitute with or without a resorbable membrane: a prospective cohort study. *J Clin Periodontol*. 2007. 34: 625-632.
37. Romanos GE, Nentwig GH. Regenerative therapy of deep peri-implant infrabony defects after CO2 laser implant surface decontamination. *Int J Periodontics Restorative Dent*. 2008. 28: 245-255.
38. Herrera D, Berglundh T, Schwarz F, Chapple I, Jepsen S, et al. Prevention and treatment of peri-implant diseases-The EFP S3 level clinical practice guideline. *J Clin Periodontology*. 2023.
39. Prathapachandran J, Suresh N. Management of peri-implantitis. *Dent Res J (Isfahan)*. 2012. 9: 516-521.
40. Nguyen-Hieu T1, Borghetti A, Aboudharam G. Peri-implantitis: from diagnosis to therapeutics. *J Investig Clin Dent*. 2012. 3: 79-94.
41. Berglundh T, Armitage G, Araujo MG, Avila-Ortiz G, Blanco J, et al. Peri-implant diseases and conditions: consensus report of workgroup 4 of the 2017 World Workshop on the Classification of Periodontal and Peri-Implant Diseases and Conditions. *J Periodontol*. 2018. 89: S313-S8.
42. Koray M, Ofluoglu D, Onal EA, Ozgul M, Ersev H, et al. Efficacy of hyaluronic acid spray on swelling, pain, and trismus after surgical extraction of impacted mandibular third molars. *Int J Oral Maxillofac Surg*. 2014. 43: 1399-1403.
43. Maria de Souza G, Elias GM, Pereira de Andrade PF, Andrade Sales KN, Galvão EL, et al. The Effectiveness of Hyaluronic Acid in Controlling Pain, Edema, and Trismus After Extraction of Third Molars: Systematic Review and Meta-Analysis. *J Oral Maxillofac Surg*. 2020. 78: 2154.e1-2154.e12.
44. Dahiya P, Kamal R. Hyaluronic Acid: a boon in periodontal therapy. *N Am J Med Sci*. 2013. 5: 309-315.
45. Pagnacco A, Vangelisti R, Erra C, Poma A. Double-blind clinical trial versus placebo of a new sodium-hyaluronate-based gingival gel. *Attual Ter In*. 1997. 15: 1-7.
46. Ballini A, Cantore S, Capodiferro S, Grassi FR. Esterified hyaluronic acid and autologous bone in the surgical correction of the infra-bone defects. *Int J Med Sci*. 2009. 6: 65-71.
47. Lopez MA, Manzulli N, D'Angelo A, Lauritano D, Papalia R, et al. The use of hyaluronic acid as an adjuvant in the management of peri-implantitis. *Journal of Biological Regulators and Homeostatic Agent*. 2017. 31: 123-127.
48. Cervino G, Meto A, Fiorillo L, Odorici A, Meto A, et al. Surface Treatment of the Dental Implant with Hyaluronic Acid: An Overview of Recent Data. *Int J Environ Res Public Health*. 2021. 18: 4670.
49. Pirnazar P, Wolinsky L, Nachnani S, Haake S, Pilloni A, et al. Bacteriostatic effects of hyaluronic acid. *J Periodontol*. 1999. 70: 370-374.
50. Sánchez-Fernández E, Magán-Fernández A, O'Valle F, Bravo M, Mesa F. Hyaluronic acid reduces inflammation and crevicular fluid IL-1 $\beta$  concentrations in peri-implantitis: a randomized controlled clinical trial. *J Periodontal Implant Sci*. 2021. 51: 63-74.
51. Kirti Shukla, Kranthi Kiran Pebilli. The Emerging role of Hyaluronic Acid in Dental Implant Procedures *Annals of International Medical and Dental* 2023. 9: 93-102.
52. Chrcanovic BR, Albrektsson T, Wennerberg A. Diabetes and oral implant failure: a systematic review. *J Dent Res*. 2014. 93: 859-867.
53. Rothwell BR, Richard EL. Diabetes mellitus: medical and dental considerations. *Spec Care Dentist*. 1984. 4: 58-65.
54. Chrcanovic BR, Albrektsson T, Wennerberg A. Diabetes and oral implant failure: a systematic review. *J Dent Res*. 2014. 93: 859-867.
55. Oates TW, Huynh-Ba G, Vargas A, Alexander P, Feine J. A critical review of diabetes, glycemic control, and dental implant therapy. *Clin Oral Implants Res*. 2013. 24: 117-127.
56. Dubey RK, Gupta DK, Singh AK. Dental implant survival in diabetic patients; review and recommendations. *Natl J Maxillofac Surg*. 2013. 4: 142-150.
57. Kormas I, Pedercini C, Pedercini A, Raptopoulos M, Alassy H, et al. Peri-Implant Diseases: Diagnosis, Clinical, Histological, Microbiological Characteristics and Treatment Strategies. A Narrative Review. *Antibiotics (Basel)*. 2020. 9: 835.
58. Ashnagar S, Nowzari H, Nokhbatolfighahaei H, Yaghoob Zadeh B, Chiniforush N, et al. Laser treatment of peri-implantitis: a literature review. *J Lasers Med Sci*. 2014. 5: 153-162.
59. Ting M, Alluri LSC, Sulewski JG, Suzuki JB, Paes Batista da Silva A. Laser Treatment of Peri-Implantitis: A Systematic Review of Radiographic Outcomes. *Dent J (Basel)*. 2022. 10: 20.
60. Rokaya D, Srimaneepong V, Wisitrasameewon W, Humagain M, Thunyakitpisal P. Peri-implantitis Update: Risk Indicators, Diagnosis, and Treatment. *Eur J Dent*. 2020. 14: 672-682.
61. Monje A., Catena A., Borgnakke W.S. Association between diabetes mellitus/hyperglycaemia and peri-implant diseases: Systematic review and meta-analysis. *J Clin Periodontol*. 2017. 44: 636-648.
62. Wagner J, Spille JH, Wiltfang J, Naujokat H. Systematic review on diabetes mellitus and dental implants: an update. *Int J Implant Dent*. 2022. 8: 1.
63. Alberti A, Morandi P, Zotti B, Tironi F, Francetti L, et al. Influence of Diabetes on Implant Failure and Peri-Implant Diseases: A Retrospective Study. *Dent J (Basel)*. 2020. 8: 70.
64. AR. Treatment of Peri-implantitis with Implantoplasty and Diode Laser. *Int J Clin Med Imaging*. 2019. 6: 658.
65. Behdin S, Monje A, Lin GH, Edwards B, Othman A, et al. Effectiveness of laser application for periodontal surgical therapy: systematic review and meta-analysis. *J Periodontol*. 2015. 86: 1352-1363.

66. Hakobyan G, Yessayan L, Khachatrayn G, Seyranyan A. The Effectiveness of Magnetic-Laser Therapy as a Supportive Treatment of Peri-Implantitis. *Am J Dent Med Probl.* 2020. 1: 1001.
67. David Herrera et al. Prevention and treatment of peri-implant diseases-The EFP S3 level clinical practice guideline. *J Clin Periodontology.* 2023.