

# Adult Febrile Infection-Related Epilepsy Syndrome Mimicking Viral Encephalitis: A Diagnostic Challenge

Bhandari A\*, Rawat A, Datta K

Department of Emergency Medicine, Max Super Specialty Hospital, Shalimar Bagh, New Delhi – 110088, India

## \*Corresponding author

Aanchal Bhandari Resident, Department of Emergency Medicine Max Super Specialty Hospital, Shalimar Bagh, New Delhi – 110088.

Received: March 13, 2026; Accepted: March 23, 2026; Published: March 31, 2026

## ABSTRACT

**Background:** Febrile Infection-Related Epilepsy Syndrome (FIRES) is an uncommon neurological disorder within the spectrum of new onset refractory status epilepticus (NORSE). It predominantly affects children, while adult presentations are rare and may create diagnostic uncertainty.

**Case Presentation:** We report a 50-year-old previously healthy man who developed super refractory status epilepticus after a nonspecific febrile illness. Early magnetic resonance imaging demonstrated bilateral mesial temporal abnormalities that were initially interpreted as viral encephalitis, leading to empirical antiviral treatment. Repeated cerebrospinal fluid analyses and extensive infectious and autoimmune investigations remained negative.

**Management and Outcome:** Seizures persisted despite multiple antiseizure medications and anesthetic therapy. Immunomodulatory treatment with corticosteroids and intravenous immunoglobulin was subsequently initiated, following which seizure activity gradually resolved and neurological recovery occurred.

**Conclusion:** Adult FIRES may resemble viral encephalitis during the early stage of illness. Repeated diagnostic reassessment and early consideration of immunomodulatory therapy may improve outcomes in NORSE spectrum disorders.

## List of Abbreviations

CMV	: Cytomegalovirus
CSF	: Cerebrospinal Fluid
EEG	: Electroencephalogram
FIRES	: Febrile Infection-Related Epilepsy Syndrome
FLAIR	: Fluid Attenuated Inversion Recovery
HHV-6	: Human Herpesvirus 6
HSV	: Herpes Simplex Virus
ICU	: Intensive Care Unit
MRI	: Magnetic Resonance Imaging
NORSE	: New Onset Refractory Status Epilepticus
PCR	: Polymerase Chain Reaction
VZV	: Varicella Zoster Virus

**Keywords:** FIRES, NORSE, Refractory Status Epilepticus, Viral Encephalitis, Immunotherapy

## Introduction

Febrile Infection-Related Epilepsy Syndrome (FIRES) is a rare and severe epileptic encephalopathy characterized by the sudden onset of refractory status epilepticus following a recent febrile illness in individuals with no prior neurological disorder. The condition is currently recognized as a subtype of new onset refractory status epilepticus (NORSE) and is diagnosed after exclusion of structural, metabolic, toxic, infectious, and autoimmune causes [1,2].

FIRES most commonly affects children, particularly school-aged patients, with a median onset between six and eight years and a slight male predominance [3]. Mortality reported in the literature ranges from approximately 10 percent to 25 percent, and survivors frequently experience long term neurological complications such as drug-resistant epilepsy or cognitive impairment [4,5]. Adult presentations remain uncommon and therefore may be overlooked during early evaluation.

Neuroimaging findings in FIRES vary during the disease course. Magnetic resonance imaging may initially appear normal but can

later show abnormalities involving limbic or cortical regions. Because there is no specific diagnostic biomarker, diagnosis depends largely on clinical progression and systematic exclusion of other causes. Early use of immunomodulatory therapy has been increasingly emphasized in the management of NORSE and FIRES [1,6].

We report a rare adult case of FIRES in which early imaging findings suggested viral encephalitis, illustrating the diagnostic complexity of this condition.

### Review of Literature

FIRES was first described in pediatric neurology literature in the early 2000s. Since that time, international consensus groups have developed recommendations outlining diagnostic evaluation and treatment strategies for NORSE and FIRES [1]. Although the exact pathophysiological mechanism remains uncertain, current evidence suggests that an abnormal inflammatory response triggered by a preceding infection may play an important role. Dysregulated cytokine signaling and persistent neuronal hyperexcitability have been proposed as potential mechanisms underlying the refractory seizure activity [7].

Adult FIRES cases are relatively rare, and available data are largely derived from small case series and retrospective studies. Published reports indicate that adult patients often require prolonged intensive care treatment and may develop significant neurological disability [8]. Early diagnosis is challenging because the initial clinical presentation and neuroimaging findings can resemble infectious or autoimmune encephalitis.

Recent therapeutic approaches have focused on controlling both seizures and the inflammatory process. Treatments such as corticosteroids, intravenous immunoglobulin, and cytokine targeted therapies have been used in patients with persistent refractory seizures, although evidence remains limited. Continued reporting of adult FIRES cases may help improve recognition and guide future treatment strategies.

### Case Presentation

#### Clinical History

A 50-year-old previously healthy male presented with recurrent generalized tonic clonic seizures and altered consciousness. Ten days before admission he experienced intermittent fever without localizing symptoms. Four days prior to presentation he developed sudden onset seizures followed by progressive confusion. Initial management at another hospital included antiseizure therapy, but persistent seizures required transfer to a tertiary neurocritical care center.

#### Examination

On admission the patient was disoriented and agitated. Vital signs were stable and systemic examination was unremarkable. Neurological examination revealed no focal deficits and pupils were equal and reactive. Initial laboratory testing demonstrated leukocytosis and elevated serum ammonia levels.

#### Investigations

Serial blood tests showed persistent leukocytosis and progressive hyperammonemia. Acute kidney injury developed during the hospital course. Cerebrospinal fluid examination including

multiplex PCR testing for HSV, CMV, HHV-6 and VZV was negative on repeated testing. Autoimmune screening including antinuclear and antineutrophil cytoplasmic antibodies was also negative.

These findings raised suspicion for FIRES in the setting of febrile illness followed by refractory seizures.

#### Neuroimaging

The initial MRI of the brain was normal. A repeat MRI performed two days later demonstrated symmetrical FLAIR hyperintensity and diffusion restriction involving the bilateral hippocampi and medial temporal lobes with additional involvement of the right insular cortex. These findings initially suggested viral encephalitis.

Subsequent imaging demonstrated extension of abnormalities into peri insular and medial frontal regions. A follow up MRI performed approximately two weeks later showed partial resolution of diffusion abnormalities, which corresponded with clinical improvement.

#### Electroencephalography

Serial EEG recordings demonstrated persistent epileptiform discharges that progressed to nonconvulsive status epilepticus despite escalation of antiseizure therapy.

#### Management and Clinical Course

The patient received levetiracetam, clobazam and phenobarbital. Because seizures persisted he required endotracheal intubation and continuous midazolam infusion under EEG monitoring. Empirical intravenous acyclovir was started due to the initial suspicion of viral encephalitis but was discontinued after repeated negative virological investigations.

Persistent seizure activity fulfilled criteria for super refractory status epilepticus. After exclusion of infectious and autoimmune causes, immunomodulatory therapy with high dose corticosteroids followed by intravenous immunoglobulin was administered.

#### Complications and Supportive Care

The ICU course was complicated by ventilator associated pneumonia, acute kidney injury and critical illness polyneuropathy. Tracheal aspirate cultures grew *Acinetobacter* species and urine cultures grew *Escherichia coli*. Because of prolonged ventilatory support a tracheostomy was performed.

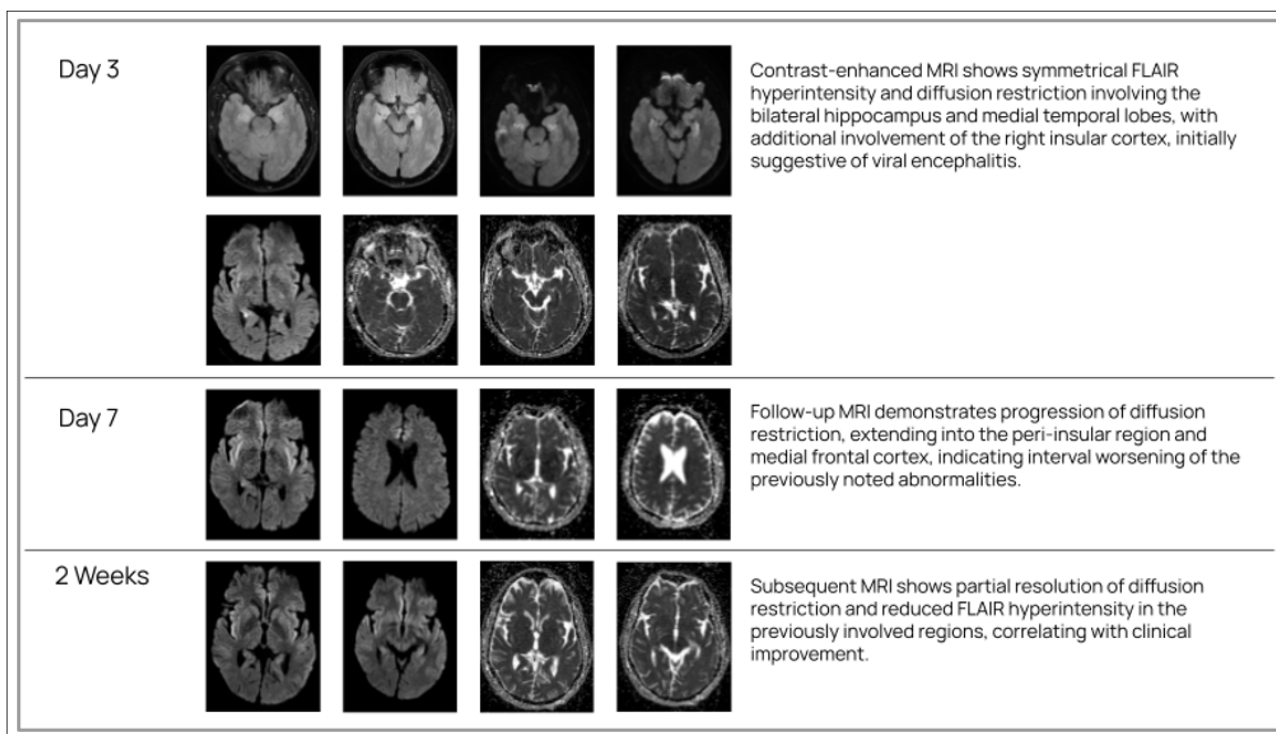
#### Outcome

Seizure activity gradually subsided approximately two weeks after initiation of immunotherapy. The patient regained consciousness and was discharged after 29 days with tracheostomy and antiseizure medications. During follow up the tracheostomy was removed and the patient remained seizure free on two medications.

#### Discussion

This case illustrates a rare adult presentation of FIRES within the NORSE spectrum. The clinical course, characterized by a febrile prodrome followed by rapid development of refractory seizures and negative infectious investigations, was consistent with current diagnostic frameworks for FIRES.

A key diagnostic difficulty was the presence of limbic abnormalities on MRI early in the illness, which strongly suggested viral encephalitis. However similar imaging findings have been reported in FIRES and may reflect inflammatory neuronal injury rather than direct viral infection. Careful correlation of imaging findings with evolving clinical and laboratory data is therefore essential.



**Figure 1:** Longitudinal MRI Brain Findings in Adult FIRES.

**Clinical Timeline**

Day	Event
Day 10	Fever without localizing symptoms
Day 4	First generalized seizure
Day 0	Hospital admission
Day 2	MRI showing bilateral temporal abnormalities
Day 5	Super refractory status epilepticus
Day 7	Corticosteroids and IVIG initiated
Day 14	Seizure control achieved
Day 29	Patient discharged

Adult FIRES is associated with prolonged intensive care hospitalization and multiple systemic complications. In this patient seizure control was achieved after initiation of immunomodulatory therapy following failure of conventional antiseizure treatment. Although the precise mechanism of benefit remains uncertain, modulation of inflammatory pathways has been proposed as a possible explanation [9,10].

**Learning Points**

- Adult FIRES is uncommon and may initially mimic viral encephalitis on MRI.
- Negative infectious investigations in patients with febrile prodrome and refractory seizures should prompt consideration of NORSE spectrum disorders.
- Early immunomodulatory therapy including corticosteroids and intravenous immunoglobulin may help control seizures in FIRES.
- Continuous diagnostic reassessment is important to avoid anchoring bias during evaluation of refractory status epilepticus.

**Limitations, Conclusions, and Recommendations**

This report describes a single patient and therefore cannot establish causal relationships between treatment and outcome. Advanced inflammatory biomarker testing was not performed, which limits mechanistic interpretation.

Nevertheless this case highlights the importance of considering FIRES in adults presenting with new onset refractory status epilepticus following a febrile illness. Persistent negative microbiological studies and progressive seizure refractoriness should prompt diagnostic reassessment.

Early recognition and timely immunomodulatory therapy may improve clinical outcomes. Future multicenter studies are needed to better understand the epidemiology and optimal treatment strategies for adult FIRES.

**Funding**

No external funding was received.

**Acknowledgments**

The authors thank the nursing staff and allied healthcare professionals of the Emergency Medicine and Neurocritical Care units at Max Super Speciality Hospital, New Delhi, for their contribution to patient care.

**References**

1. Wickström R, Taraschenko O, Dilena R, Payne ET, Specchio N, et al. the International NORSE Consensus Group International consensus recommendations for management of new onset refractory status epilepticus (NORSE) including febrile infection-related epilepsy syndrome (FIRES): Summary and clinical tools. *Epilepsia*. 2022. 63: 2827–2839.

2. Sheikh Z, Renzel R, Serafini A. A practical approach to in-hospital management of NORSE and FIRES. *Neurology*. 2023. 100: 219-230.
3. Wickström R, Taraschenko O, Dilella R, Payne ET, Specchio N, et al. the International NORSE Consensus Group International consensus recommendations for management of new onset refractory status epilepticus (NORSE) including febrile infection-related epilepsy syndrome (FIRES): Summary and clinical tools. *Epilepsia*. 2022. 63: 2827–2839.
4. van Baalen A, Vezzani A, Häusler M, Kluger G. Febrile Infection-Related Epilepsy Syndrome: Clinical Review and Hypotheses of Epileptogenesis. *Neuropediatrics*. 2017. 48: 5-18.
5. Saad K, Aboelgheet AM, Hamed Y, Alruwaili TAM, Ibrahim MFM, Febrile Infection-Related Epilepsy Syndrome (FIRES) in children: a retrospective cohort study. *Eur J Pediatr*. 2025. 184: 206.
6. Lam SK, So EL, Osman A. Short and long term outcomes of FIRES. *Epilepsia*. 2018. 59: 84-91.
7. Reppucci D, Scherer C, Küenburg E. FIRES pathophysiology and treatment strategies. *Mol Cell Pediatr*. 2022. 9: 5.
8. Shi X, Wang Y, Wang X, Kang X, Yang F, et al. Long-term outcomes of adult cryptogenic febrile infection-related epilepsy syndrome (FIRES). *Front Neurol*. 2023. 4: 1081388.
9. Nass RD, Wagner M, Knappe N. Functional outcomes in adult FIRES survivors. *Eur J Neurol*. 2021. 28: 1900-1908.
10. Zeiler FA, Matuszczak M, Teitelbaum J, Kazina CJ, Gillman LM. Intravenous immunoglobulins for refractory status epilepticus, part I: A scoping systematic review of the adult literature. *Seizure*. 2017. 45: 172-180